DIAGNÓSTICO DE DESORDENS ORAIS POTENCIALMENTE MALIGNAS E DO CÂNCER DE BOCA

Márcio Campos

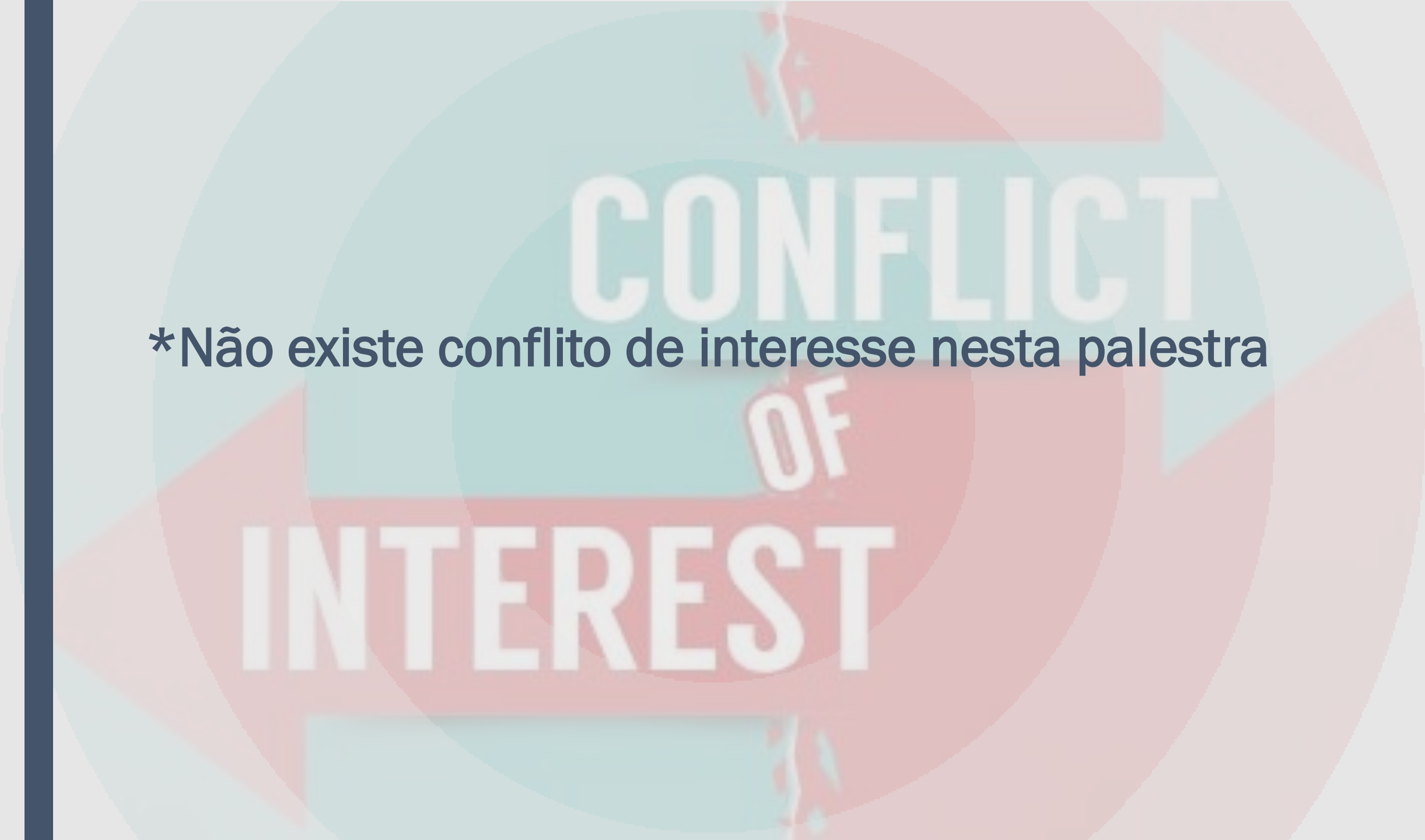

*Não existe conflito de interesse nesta palestra

DESORDENS ORAIS POTENCIALMENTE MALIGNAS

Received: 20 September 2020 | Revised: 21 October 2020 | Accepted: 25 October 2020
DOI: 10.1111/odi.13704

REVIEW ARTICLE

ORAL DISEASES WILEY

Oral potentially malignant disorders: A consensus report from an international seminar on nomenclature and classification, convened by the WHO Collaborating Centre for Oral Cancer

Saman Warnakulasuriya[1] | Omar Kujan[2] | José M. Aguirre-Urizar[3] | José V. Bagan[4,5] | Miguel Ángel González-Moles[6,7] | Alexander R. Kerr[8] | Giovanni Lodi[9] | Fernanda Weber Mello[10] | Luis Monteiro[11] | Graham R. Ogden[12] | Philip Sloan[13] | Newell W. Johnson[14,15]

[1]The WHO Collaborating Centre for Oral Cancer and Faculty of Dentistry, Oral and Craniofacial Sciences, King's College London, London, UK
[2]UWA Dental School, The University of Western Australia, Perth, WA, Australia
[3]Oral and Maxillofacial Medicine & Pathology Unit, Department of Stomatology II, Faculty of Medicine and Nursery, University of the Basque Country/EHU, Bilbao, Spain
[4]Oral Medicine, Valencia University, Valencia, Spain
[5]Department of Oral and Maxillofacial Surgery, University General Hospital, Valencia, Spain
[6]School of Dentistry, University of Granada, Granada, Spain
[7]Biohealth Research Institute (IBS), Granada, Spain
[8]Department of Oral and Maxillofacial Pathology, Radiology, and Medicine, New York University College of Dentistry, New York, NY, USA
[9]Dipartimento di Scienze Biomediche, Chirurgiche e Odontoiatriche, Università degli Studi di Milano, Milano, Italy
[10]Federal University of Santa Catarina, Florianópolis, Brazil
[11]CESPU, Instituto de Investigação e Formação Avançada em Ciências e Tecnologias da Saúde (IINFACTS), IUCS - Instituto Universitário de Ciências da Saúde, Gandra, Portugal
[12]Department of Oral Surgery, Dundee Dental School, Dundee, Scotland, UK
[13]School of Dental Sciences, Faculty of

Abstract

Oral potentially malignant disorders (OPMDs) are associated with an increased risk of occurrence of cancers of the lip or oral cavity. This paper presents an updated report on the nomenclature and the classification of OPMDs, based predominantly on their clinical features, following discussions by an expert group at a workshop held by the World Health Organization (WHO) Collaborating Centre for Oral Cancer in the UK. The first workshop held in London in 2005 considered a wide spectrum of disorders under the term "potentially malignant disorders of the oral mucosa" (PMD) (now referred to as oral potentially malignant disorders: OPMD) including leukoplakia, erythroplakia, proliferative verrucous leukoplakia, oral lichen planus, oral submucous fibrosis, palatal lesions in reverse smokers, lupus erythematosus, epidermolysis bullosa, and dyskeratosis congenita. Any new evidence published in the intervening period was considered to make essential changes to the 2007 classification. In the current update, most entities were retained with minor changes to their definition. There is sufficient evidence for an increased risk of oral cancer among patients diagnosed with "oral lichenoid lesions" and among those diagnosed with oral manifestations of 'chronic graft-versus-host disease'. These have now been added to the list of OPMDs. There is, to date, insufficient evidence concerning the malignant potential of chronic hyperplastic candidosis and of oral exophytic verrucous hyperplasia to consider these conditions as OPMDs. Furthermore, due to lack of clear evidence of an OPMD in epidermolysis bullosa this was moved to the category with limited evidence. We recommend the establishment of a global research consortium to further study the natural history of OPMDs based on the classification and nomenclature proposed here. This will require multi-center longitudinal studies with uniform diagnostic criteria to improve the identification and cancer risk stratification of patients with OPMDs, link them to evidence-based interventions, with a goal to facilitate the prevention and management of lip and oral cavity cancer.

 © 2020 Wiley Periodicals LLC

WHO Classification of Tumours * 5th Edition

Head and Neck Tumours

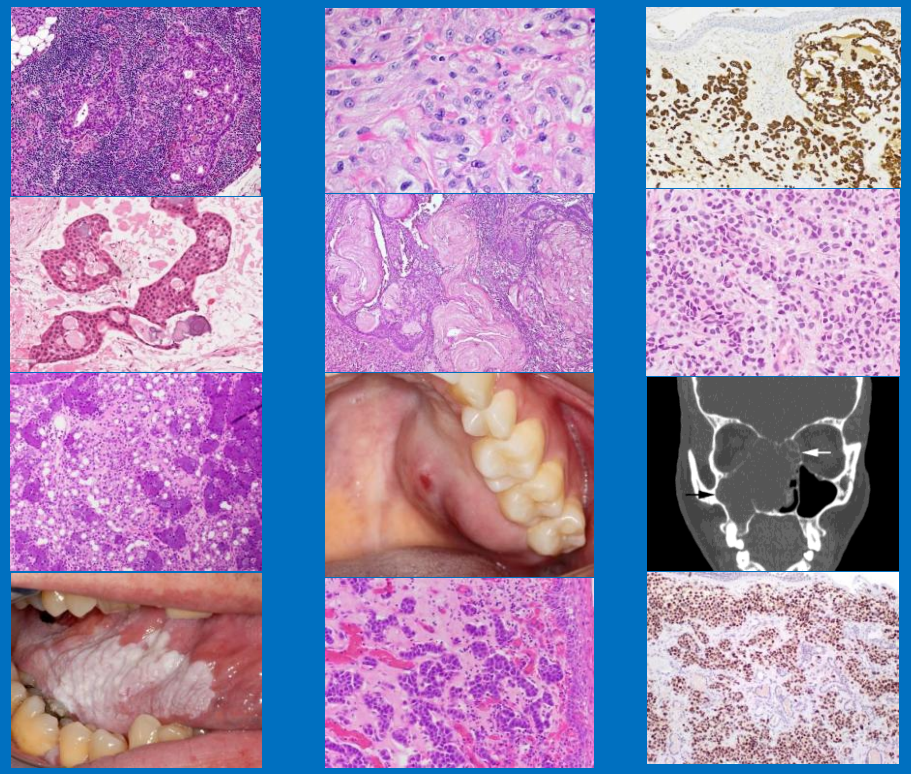

World Health Organization

Desordens orais potencialmente malignas são um grupo heterogêneo de condições clinicamente definidas e associadas com um risco variável de progressão para carcinoma escamocelular oral. A maioria produz lesões clinicamente visíveis

OMS, 2022

Desordens orais potencialmente malignas são qualquer anormalidade da mucosa oral que é associada com um risco estatisticamente aumentado de desenvolver um câncer oral

Warnakulasuriya et al, 2022

TABLE 1 Recommended definitions for OPMDs

Disorder	Definition	Source
Leukoplakia	A predominantly white plaque of questionable risk having excluded (other) known diseases or disorders that carry no increased risk for cancer	Warnakulasuriya et al, 2007
Proliferative Verrucous Leukoplakia (PVL)	Progressive, persistent, and irreversible disorder characterized by the presence of multiple Leukoplakia that frequently become warty	WHO Collaborating Centre 2020
Erythroplakia	A predominantly fiery red patch that cannot be characterized clinically or pathologically as any other definable disease	WHO Collaborating Centre, 2007
Oral Submucous Fibrosis (OSF)	A chronic, insidious disease that affects the oral mucosa, initially resulting in loss of fibroelasticity of the lamina propria and as the disease advances, results in fibrosis of the lamina propria and the submucosa of the oral cavity along with epithelial atrophy	Modified from: World Workshop on Oral Medicine V, Kerr et al. (2011)
Oral Lichen Planus (OLP)	A chronic inflammatory disorder of unknown etiology with characteristic relapses and remissions, displaying white reticular lesions, accompanied or not by atrophic, erosive and ulcerative and/or plaque type areas. Lesions are frequently bilaterally symmetrical. Desquamative gingivitis may be a feature	WHO Collaborating Centre 2020
Actinic Keratosis (Actinic Cheilitis) (AK/AC)	A disorder that results from sun damage and affects exposed areas of the lips, most commonly the vermilion border of the lower lip with a variable presentation of atrophic and erosive areas and white plaques	WHO Collaborating Centre 2020
Palatal Lesions in Reverse Smokers	White and/or red patches affecting the hard palate in reverse smokers, frequently stained with nicotine	WHO Collaborating Centre 2020
Oral Lupus Erythematosus (OLE)	An autoimmune connective tissue disease which may affect the lip and oral cavity, where it presents as an erythematous area surrounded by whitish striae, frequently with a target configuration	WHO Collaborating Centre 2020
Dyskeratosis Congenita (DC)	A rare cancer-prone inherited bone marrow failure syndrome caused by aberrant telomere biology. It is characterized clinically by the presence of the diagnostic triad of dysplastic nails, lacy reticular skin pigmentation and oral leukoplakia	Ballew and Savage (2013)
Newly included in 2020 classification		
Oral Lichenoid Lesion (OLL)	Oral lesions with lichenoid features but lacking the typical clinical or histopathological appearances of OLP, that is, may show asymmetry or are reactions to dental restorations or are drug-induced	WHO Collaborating Centre 2020
Oral Graft versus Host Disease (OGVHD)	Clinical and histopathological presentations similar to oral lichen planus in a patient developing an autoimmune, multi-organ complication after allogeneic hematopoietic cell transplantation	WHO Collaborating Centre 2020
Removed from the 2020 classification due to limited evidence		
Oral Epidermolysis Bullosa (OEB)	A severe epidermal fragility disorder associated with trauma-induced blistering, progressive soft tissue scarring, and increased risk of epidermal cancer	Fritsch et al. (2008)

Warnakulasuriya, et al, 2021

Etiologia das DOPMs

- Tabaco (com e sem fumaça)
- Álcool
- Noz de areca (com ou sem tabaco)
- HPV de alto risco
- Radiação solar
- Susceptibilidade genética
- Microbioma oral
- Imunidade
- Etiologia não identificada

OMS, 2022

LEUCOPLASIA

Aspectos clínicos e conduta clínica

Leucoplasia

Leucoplasia é um termo clínico usado para descrever placa predominantemente branca de risco questionável após exclusão de outras doenças conhecidas

Warnakulasuriya et al, 2007; OMS, 2022

Leucoplasia

- Homens
- Acima de 40 anos
- Fumantes
- 1 a 4% nos países ocidentais

Neville et al, 2016; Ganesh et al, 2018; OMS, 2022

Leucoplasia

- Homogênea
- Não-homogênea
- LVP

Leucoplasia homogênea

Lesão branca, de superfície plana, aparência delgada, que pode exibir fendas não profundas e possui superfície lisa, enrugada ou corrugada com textura consistente em toda a área

Axéll et al, 1996; OMS, 2017; Ganesh et al, 2018

Leucoplasia não-homogênea

Lesão branca e vermelha de superfície irregular, nodular ou exofítica

OMS, 2017; Ganesh et al, 2018

Leucoplasia verrucosa proliferativa

A leucoplasia verrucosa proliferativa (LVP) é uma variante clínico-patológica da leucoplasia oral multifocal, persistente e progressiva, com alta taxa de recorrência e alto risco de progressão para carcinoma espinocelular

OMS, 2017

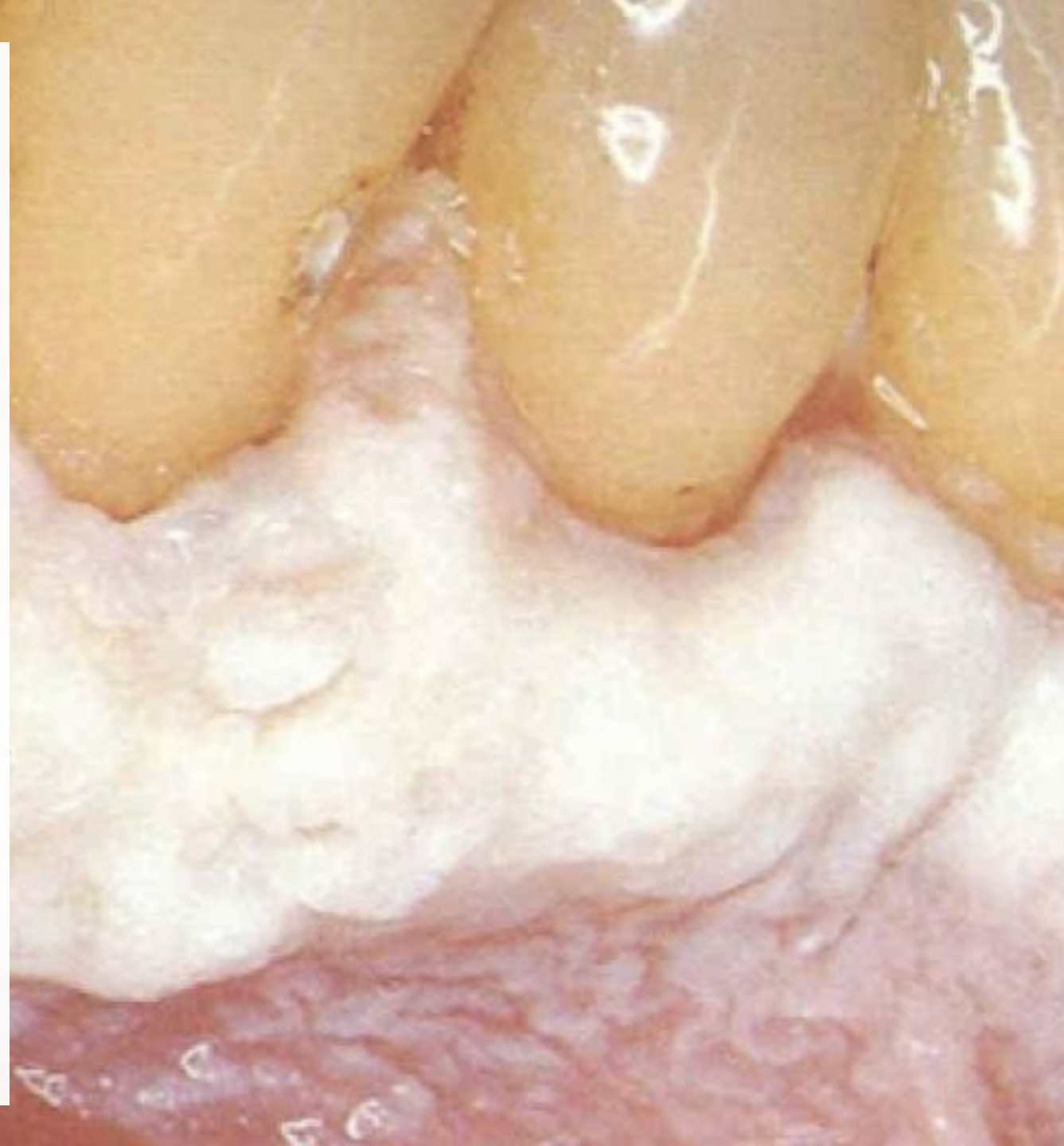

Leucoplasia Verrucosa Proliferativa

- Pacientes mais velhos (>60 anos)
- ♀ /♂ - 4:1
- Lesões multifocais, verrucosas ou não
- Gengiva, mucosa alveolar e palato
- Língua e assoalho de boca menos comuns

OMS, 2017

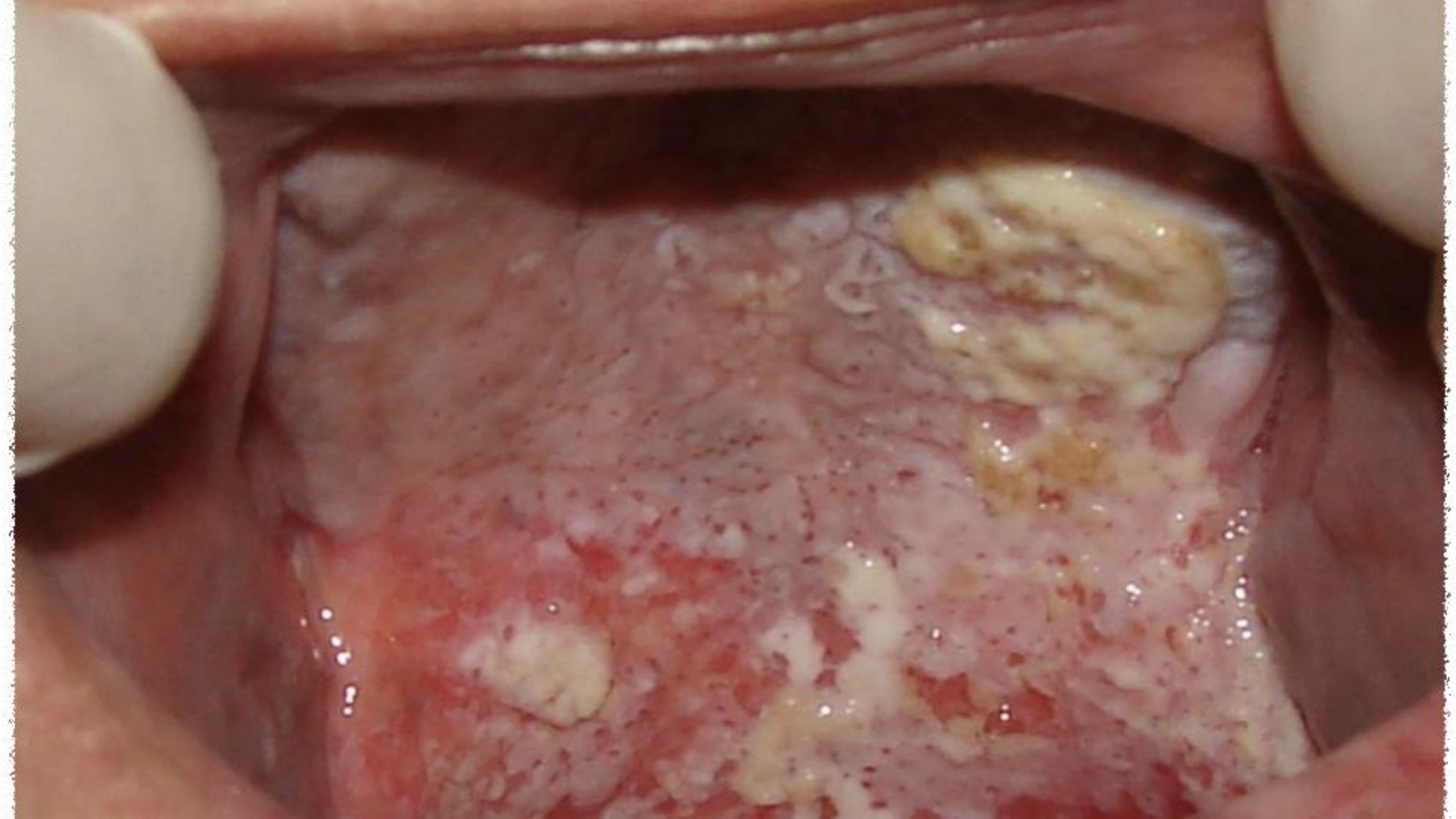

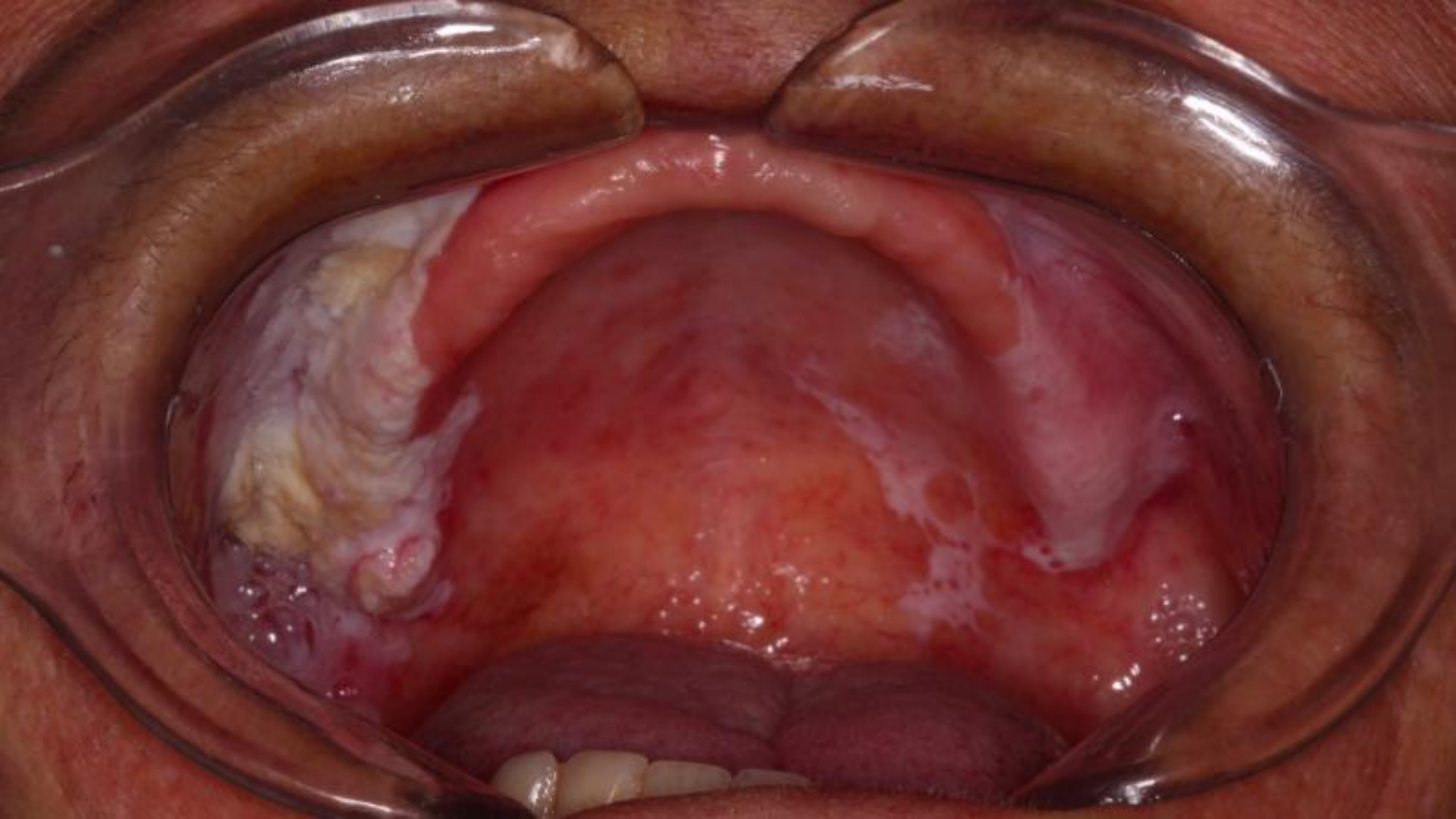

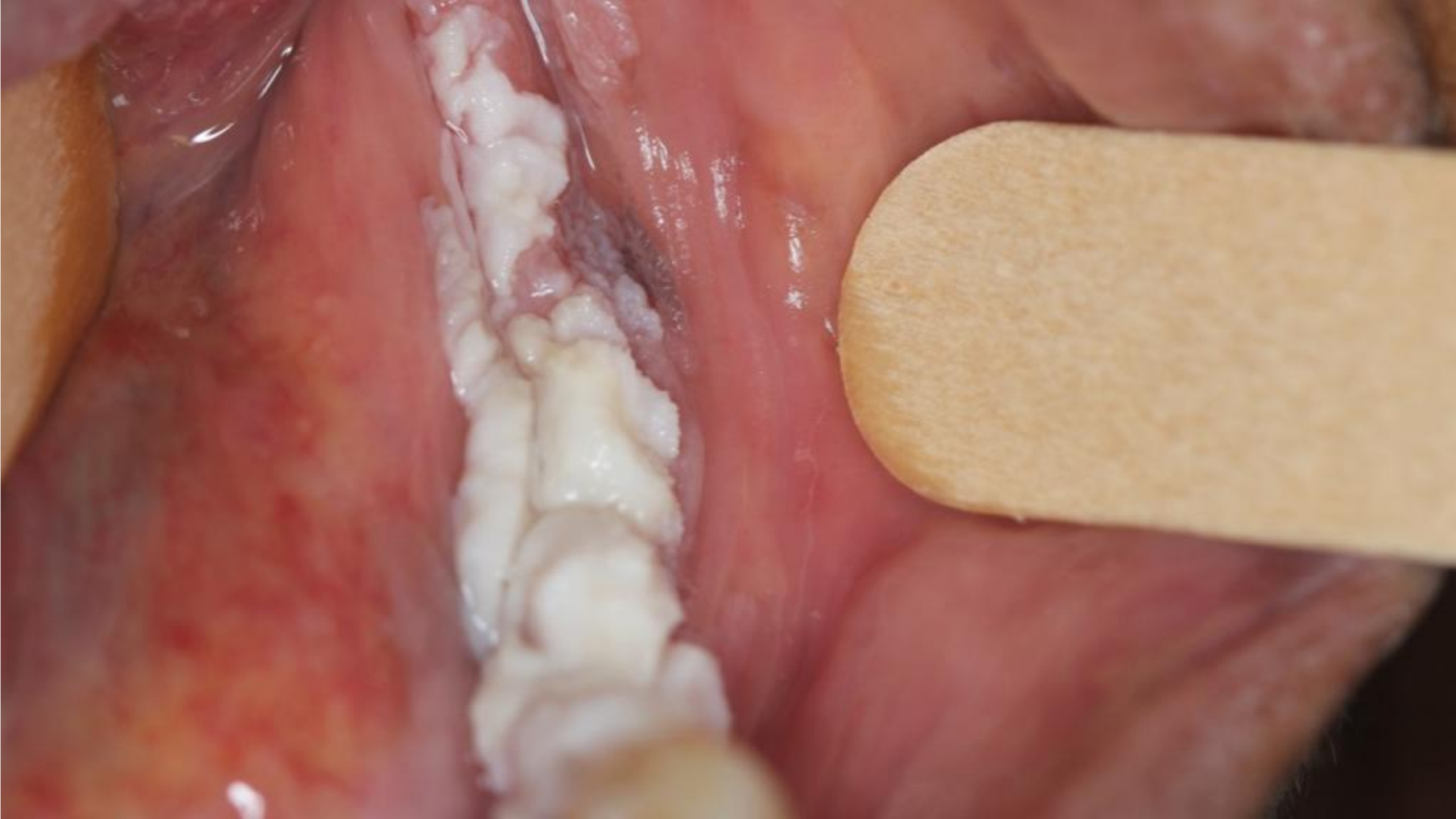

Fatores prognósticos

- Altas taxas de transformação maligna
- Carcinomas espinocelulares ou verrucosos
- Curso imprevisível
- Carcinomas primários múltiplos a partir de LVPs não são incomuns

Ganesh et al, 2018; Warnakulasuriya et al, 2021; OMS, 2022

Fatores preditivos

- Presença de displasia epitelial
- Leucoplasia não-homogênea e LVP
- Tamanho (>200mm)
- Localização (assoalho de boca e bordo lateral de língua)

OMS, 2017

Conduta

- Biópsia
- Tratamento cirúrgico
- Acompanhamento
- Ablação a laser

Prognóstico

- Transformação: 1 a 2%
- Com displasia: 12%

Table 7
Management of leukoplakia

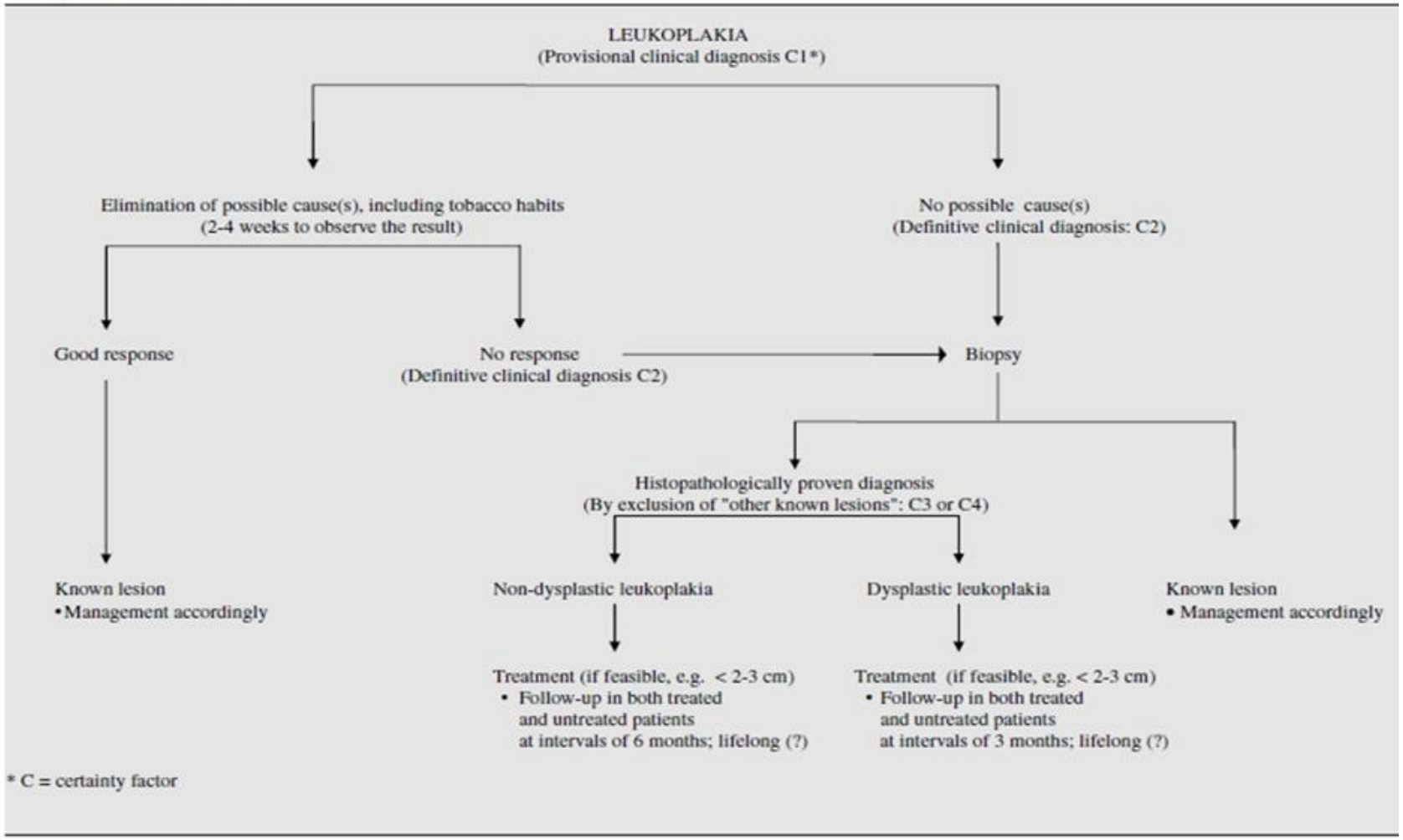

van der Waal, 2009

ERITROPLASIA

Aspectos clínicos e conduta clínica

Eritroplasia

Manchas vermelhas que não podem ser definidas clínica ou patologicamente como qualquer outra lesão definível

Warnakulasuriya, et al, 2021; OMS, 2022

Eritroplasia

- Sem predileção por sexo
- Entre 60 e 75 anos
- Assoalho de boca, mucosa jugal e palato mole
- Prevalência de 0,02% a 0,83% nos países ocidentais

OMS, 2017; Ganesh et al, 2018

Conduta

- Remover possíveis fatores irritativos
- Realização de biópsia
- Remoção cirúrgica total, caso possível
- Ablação a laser
- Acompanhamento por longos períodos
- Recidiva e envolvimento multifocal comuns
- Transformação maligna em 14% a 50% dos casos

Neville et al, 2016; Ganesh et al, 2018

QUEILITE ACTÍNICA

Aspectos clínicos e conduta clínica

Queilite actínica

Condição potencialmente maligna comum do vermelhão do lábio inferior que resulta de uma exposição progressiva excessiva ao espectro ultravioleta da luz solar

Neville et al, 2016

Queilite actínica

- Gênero masculino (10:1)
- Acima dos 45 anos
- Atrofia do vermelhão do lábio
- Apagamento da margem
- Ulceração focal crônica

Conduta

- Orientação
- Barreiras físicas e químicas
- Biópsia (endurecimento, espessamento, áreas leucoplásicas e ulceradas)
- Ablação a laser
- Aplicação tópica de 5-fluorouracil, imiquimod
- Terapia fotodinâmica e quimioexfoliação
- Acompanhamento de longa duração

Carcinoma Epidermoide Oral

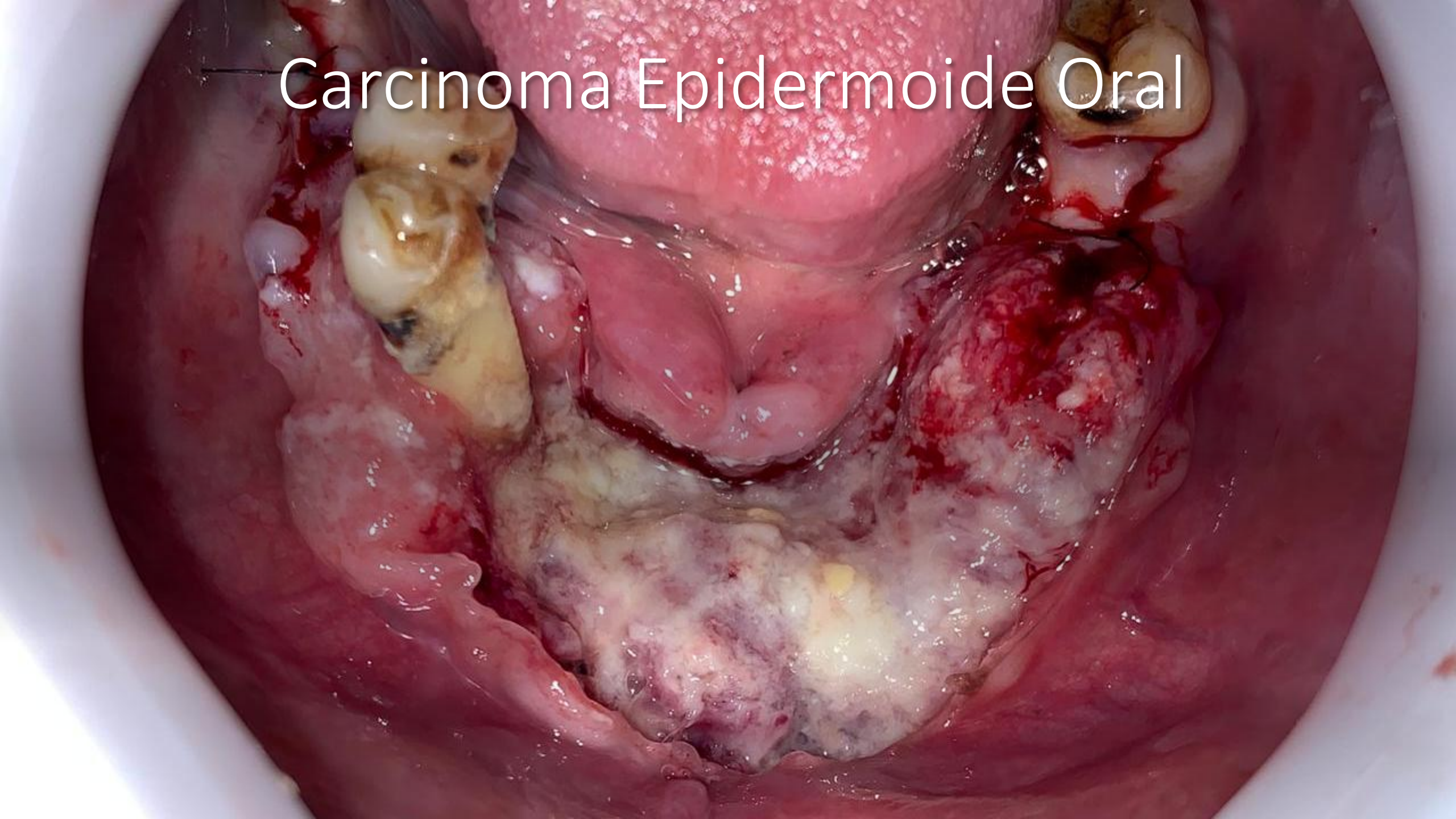

Carcinoma epidermoide

O carcinoma epidermoide oral é uma neoplasia maligna que surge do epitélio da mucosa oral e apresenta diferenciação escamosa variável

OMS, 2022

ETIOLOGIA

- Fumo
- Álcool
- Radiação solar
- Agentes biológicos (HPV)
- Disbiose

DOI: 10.1590/1980-5497201500040017

ORIGINAL ARTICLE / *ARTIGO ORIGINAL*

Associated factors with oral cancer: a study of case control in a population of the Brazil's Northeast

Fatores associados ao câncer de boca: um estudo de caso-controle em uma população do Nordeste do Brasil

Jarielle Oliveira Mascarenhas Andrade[I], Carlos Antonio de Souza Teles Santos[II], Márcio Campos Oliveira[III]

REV BRAS EPIDEMIOL OCT-DEC 2015; 18(4): 894-905

ABSTRACT: ***Objective:*** This study aimed at assessing the association between factors such as age, sex, skin color, occupation, educational level, marital status, place of residence, and tobacco and alcohol consumptions and oral cancer in individuals in a city in the northeast of Brazil between 2002 and 2012. ***Methods:*** This is a case–control study. The case group consisted of 127 people attended at the Oral Injury Reference Center with histopathological diagnosis of oral squamous cell carcinoma. The control group consisted of 254 individuals treated at the same center. The study considered two controls for each case. The cases and controls were adjusted according to sex and age. Univariate and bivariate analyses were performed (Pearson χ^2-test) to verify the correlation between the dependent variable (oral cancer) and the independent variables; odds ratio (OR) and the confidence interval of 95% (95%CI) were calculated. Finally, in the multivariate analysis, it was used as the hierarchical model with logistic regression to explain the interrelationships between the independent variables and oral cancer. ***Results:*** Consumption of more than 20 cigarettes per day [OR = 6.64; 95%CI 2.07 – 21.32; $p \leq 0.001$], an excessive alcohol consumption [OR = 3.25; 95%CI 1.03 – 10.22; $p \leq 0.044$], and the synergistic consumption of tobacco and alcohol [OR = 9.65; 95%CI 1.57 – 59.08; $p \leq 0.014$] are the most important risk factors for oral cancer. ***Conclusion:*** It was concluded that tobacco and alcohol consumptions are the most important factors for the development of oral cancer. Sociodemographic factors were not associated with this neoplasm after adjusting for smoking and drinking.

Keywords: Mouth neoplasms. Squamous cell carcinoma. Epidemiology. Risk factors. Case–controls studies. Odds ratio.

Oral Surgery, Oral Medicine, Oral Pathology and Oral Radiology
Available online 8 April 2022
In Press, Journal Pre-proof

State-of-the-science concepts of HPV-related oropharyngeal squamous cell carcinoma: A comprehensive review

Brendo Vinicius Rodrigues Louredo DDS, MSc [a], Ana Carolina Prado-Ribeiro DDS, PhD [b], Thaís Bianca Brandão DDS, PhD [b, c], Joel B. Epstein DDS, PhD [d, e], Cesar Augusto Migliorati DDS, PhD [f], Alicia Rumayor Piña DDS, PhD [g], Luiz Paulo Kowalski MD, PhD [h, i], Pablo Agustin Vargas DDS, PhD, FRCPath [a], Márcio Ajudarte Lopes DDS, PhD [a], Alan Roger Santos-Silva DDS, PhD [a]

[a] Oral Diagnosis Department, Piracicaba Dental School, University of Campinas (UNICAMP), Piracicaba, Brazil
[b] Dental Oncology Service, São Paulo State Cancer Institute (ICESP), School of Medicine, University of São Paulo (USP), São Paulo, Brazil
[c] Oral Medicine Department, Hospital Sírio-Libanês, São Paulo, Brazil
[d] Cedars-Sinai Health System, Los Angeles, California, United States of America
[e] City of Hope Comprehensive Cancer Center, Duarte, California, United States of America
[f] College of Dentistry, University of Florida, Gainesville, Florida, United States of America
[g] Faculty of Dentistry, Autonomous University of Coahuila, Saltillo, Mexico
[h] Department of Head and Neck Surgery and Otorhinolaryngology, AC Camargo Cancer Center (ACCCC), Sao Paulo, Brazil
[i] Department of Head and Neck Surgery, São Paulo State Cancer Institute (ICESP), School of Medicine, University of São Paulo (USP), São Paulo, Brazil.

Received 12 December 2021, Revised 30 March 2022, Accepted 31 March 2022, Available online 8 April 2022.

Relevância clínica:

1. Pacientes com esta doença geralmente são homens jovens (40-50 anos ao diagnóstico) não tabagistas que apresentam tumores primários pequenos e pouco sintomáticos em tonsila palatina ou base de língua, com metástases cervicais de aparência cística
2. A quantidade de parceiros de sexo oral, a frequência da realização de sexo oral e o tempo de início da prática do sexo oral parecem impactar o risco do desenvolvimento do câncer de orofaringe
3. ASCO/CAP recomendam a investigação do status tumoral por meio da combinação da imunoexpressão de p16 seguida de estudos específicos (PCR ou ISH) para todos os carcinomas de orofaringe
4. O status tumoral positivo para HPV tem potencial para modificar o tratamento oncológico com tendência à melhor resposta para quimiorradioterapia concomitante (não cirúrgicos)
5. A vacinação de crianças/adolescentes masculinos e femininos contra o HPV é uma estratégia de prevenção primária universalmente disponível no Brasil via SUS

Distribuição espacial das taxas ajustadas de incidência por 100 mil habitantes, estimadas para o ano de 2023

Câncer de cavidade oral

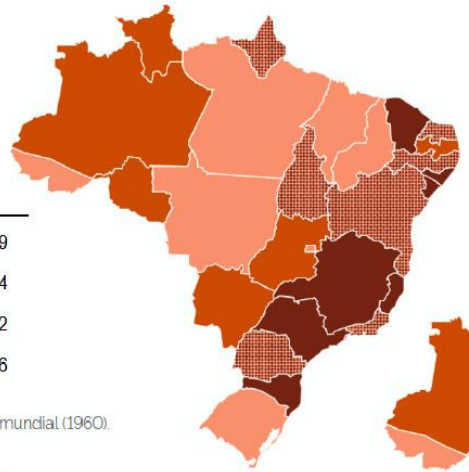

Total

- 6,25 – 8,79
- 5,03 – 6,24
- 3,77 – 5,02
- 2,54 – 3,76

[a]População padrão mundial (1960).

[a]População padrão mundial (1960).

Câncer de laringe

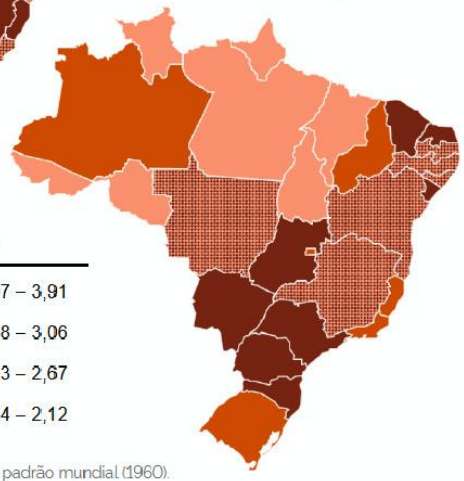

Total

- 3,07 – 3,91
- 2,68 – 3,06
- 2,13 – 2,67
- 1,54 – 2,12

[a]População padrão mundial (1960).

Estimativa INCA 2023: incidência de câncer no Brasil

Localização primária	Casos	%
Próstata	71.730	30,0%
Cólon e Reto	21.970	9,2%
Traquéia, Brônquio e Pulmão	18.020	7,5%
Estômago	13.340	5,6%
Cavidade Oral	10.900	4,6%
Esôfago	8.200	3,4%
Bexiga	7.870	3,3%
Laringe	6.570	2,7%
Linfoma não Hodgkin	6.420	2,7%
Fígado	6.390	2,7%

Localização primária	Casos	%
Mama feminina	73.610	30,1%
Cólon e Reto	23.660	9,7%
Colo do útero	17.010	7,0%
Traquéia, Brônquio e Pulmão	14.540	6,0%
Glândula Tireoide	14.160	5,8%
Estômago	8.140	3,3%
Corpo do útero	7.840	3,2%
Ovário	7.310	3,0%
Pâncreas	5.690	2,3%
Linfoma não Hodgkin	5.620	2,3%

*Números arredondados para múltiplos de 10

Os cânceres de cavidade oral e de laringe, respectivamente, são o quinto e oitavo tipos mais comuns de câncer entre os homens.

INCA INSTITUTO NACIONAL DE CÂNCER

HEADSpAcE

FAPESP

CARACTERÍSTICAS CLÍNICAS

- ✓Homens mais velhos
- ✓Fumantes e etilistas crônicos
- ✓Radiação solar
- ✓Assintomáticos no início
- ✓Aumento da incidência em mulheres

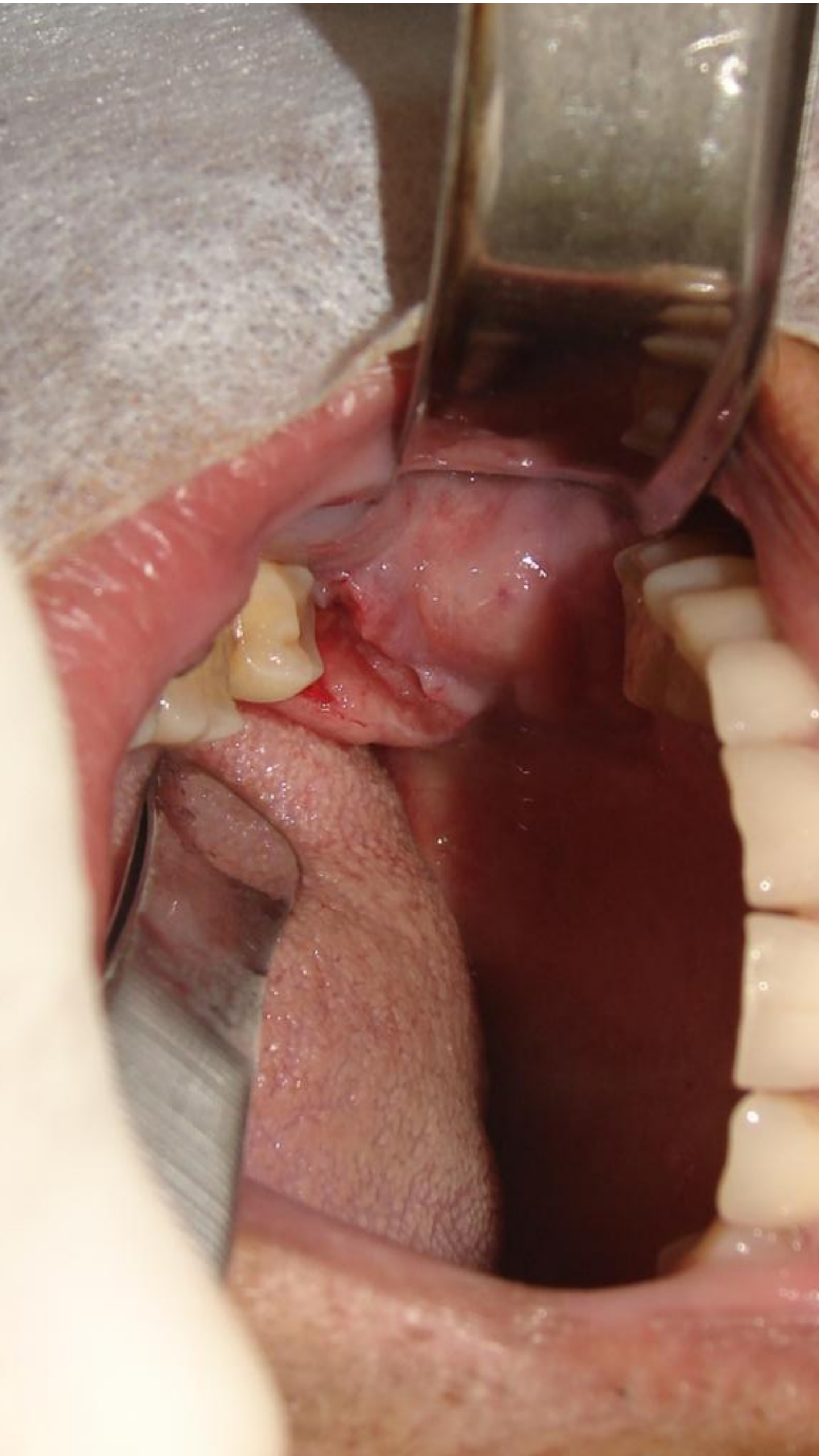

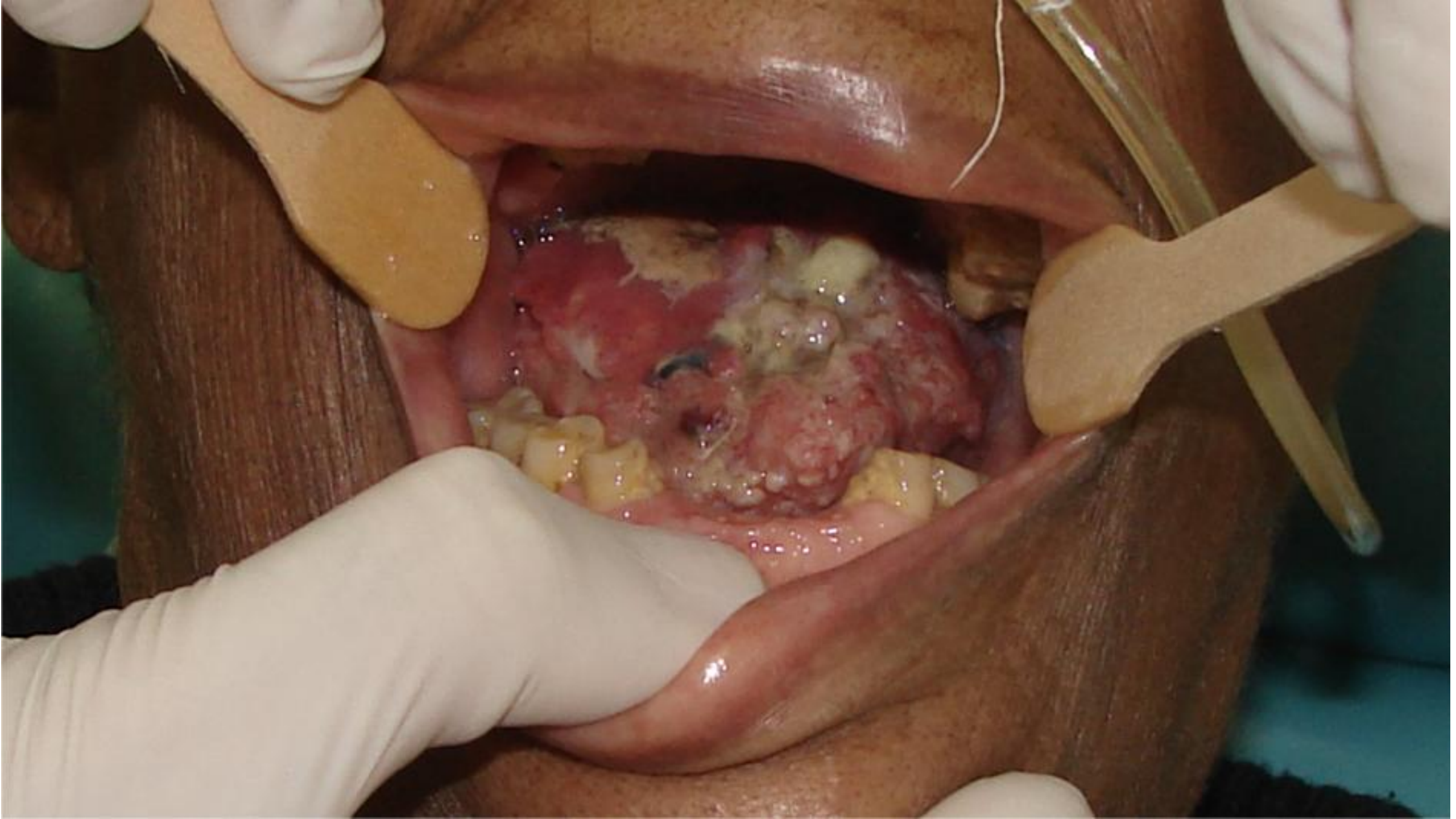

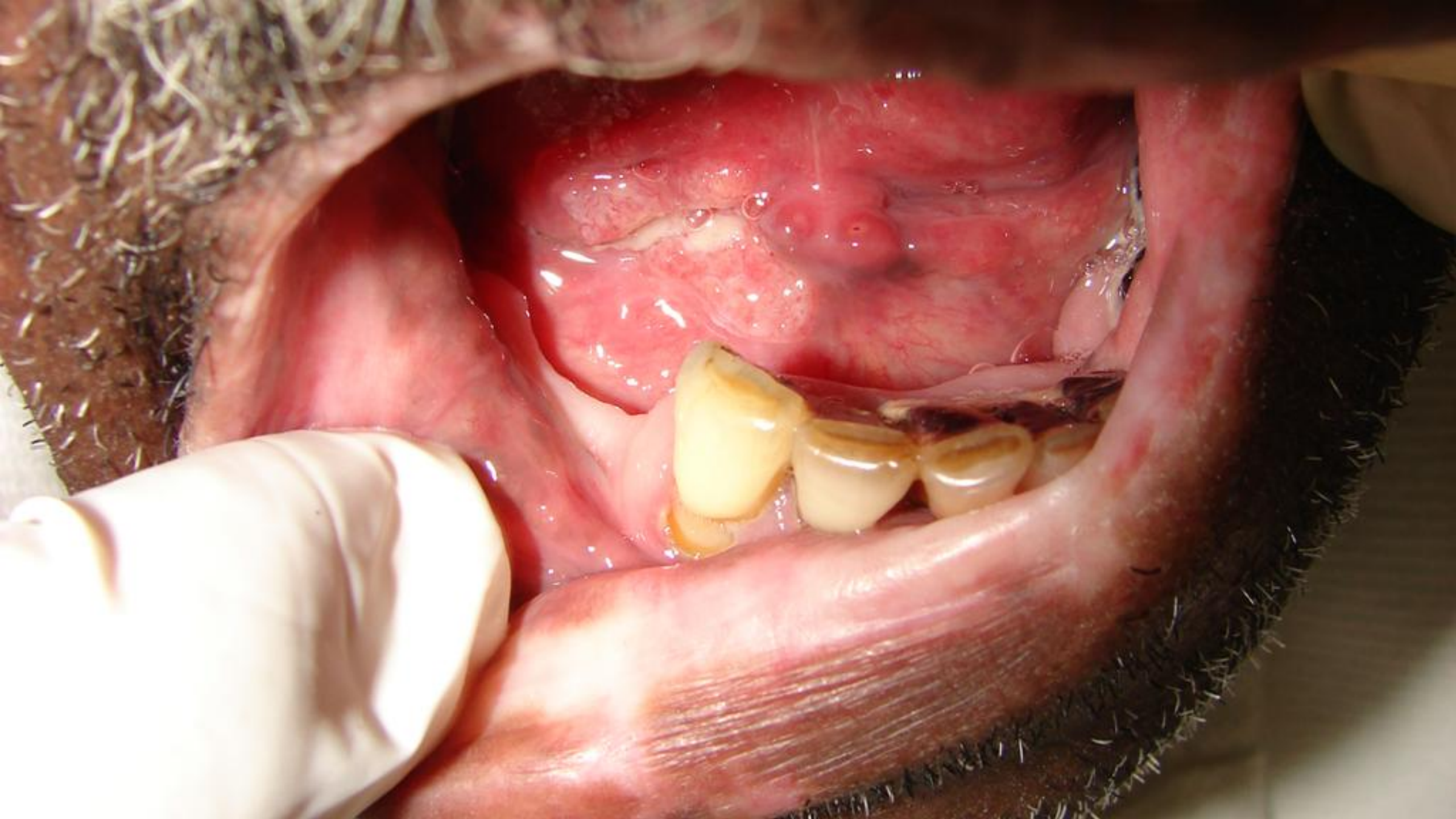

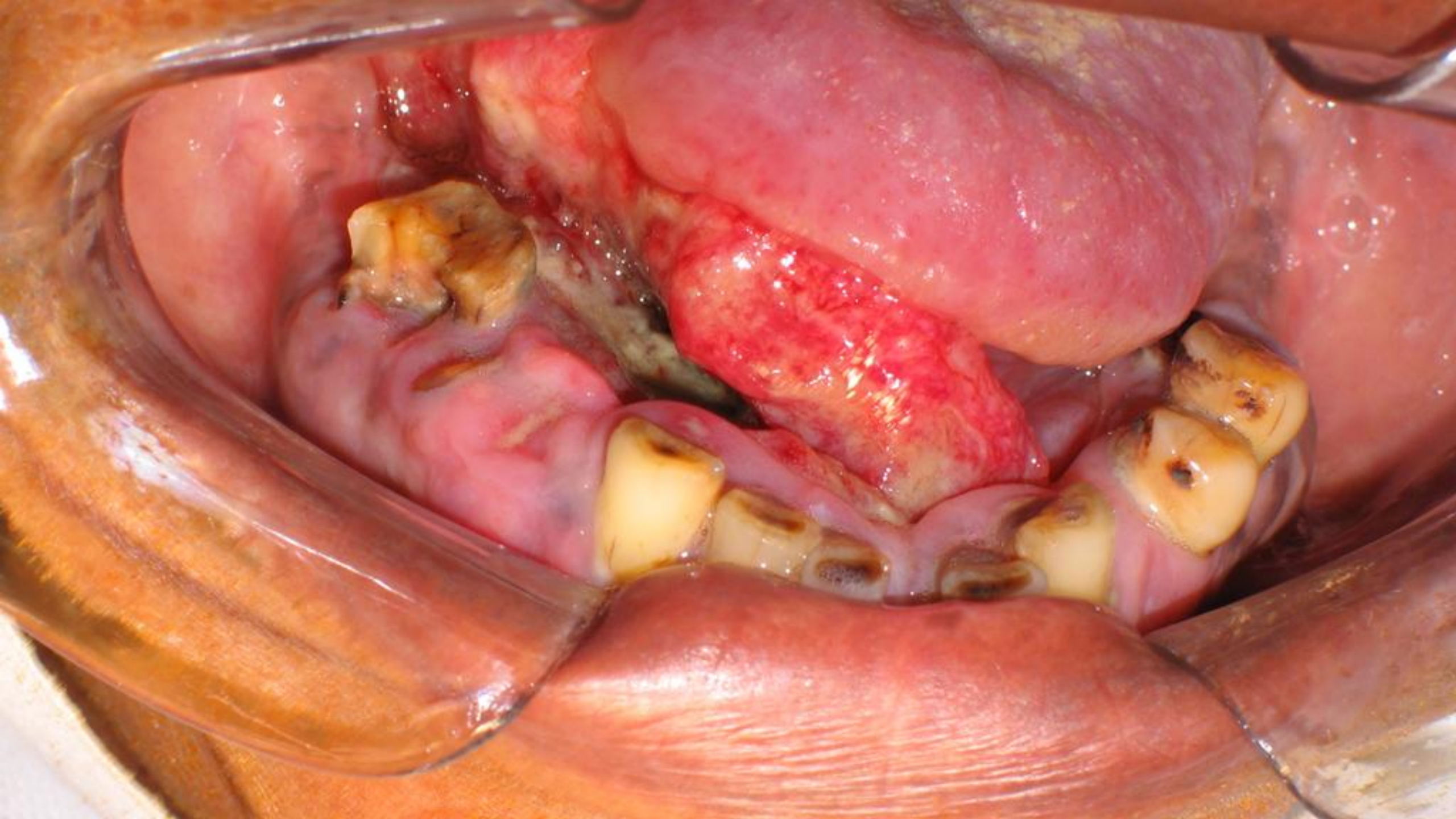

Conduta

- Encaminhamento ao cirurgião de cabeça e pescoço após diagnóstico
- Tratamento cirúrgico exclusivo ou em combinação
- Tratamento radioterápico exclusivo ou em combinação
- Novas modalidades terapêuticas
- Prognóstico dependente do estadiamento do tumor
- Sobrevida de 5 anos em até 50% dos casos
- Lábio com melhor prognóstico e língua com pior

NUCAO
NÚCLEO DE CÂNCER ORAL

NUPESCAP

OBRIGADO!

campos@uefs.br

@marciocampos71

marcio.campos.oliveira

(75)99122-9283