

Aviso de isenção de responsabilidade: Este é um PDF gerado por máquina do conteúdo selecionado de nossos produtos. Essa funcionalidade é fornecida somente para sua conveniência e não deve nunca substituir o PDF escaneado originalmente. Nem a Cengage Learning nem suas licenciadas atestam ou garantem de alguma maneira esses PDFs gerados automaticamente. O PDF é gerado automaticamente "NO FORMATO EM QUE SE ENCONTRA" e "DE ACORDO COM A DISPONIBILIDADE" e não é mantido em nosso sistema. A CENGAGE LEARNING E SUAS LICENCIADAS ESPECIFICAMENTE SE ISENTAM DE RESPONSABILIDADE SOBRE QUALQUER GARANTIA EXPRESSA OU IMPLÍCITA, SEM LIMITAÇÕES, INCLUSIVE GARANTIAS DE DISPONIBILIDADE, PRECISÃO, PONTUALIDADE, COMPLETUDE, LEGALIDADE, COMERCIALIZABILIDADE OU ADEQUAÇÃO A UM PROPÓSITO ESPECÍFICO. O uso do PDF automático está sujeito a todas as restrições de uso incluídas no Contrato de Licença e Assinatura da Cengage Learning e/ou nos Gale Academic OneFile Termos e Condições. Ao usar a funcionalidade de PDF automático, você concorda em renunciar a qualquer alegação contra a Cengage Learning ou suas licenciadas pelo uso dessa funcionalidade e qualquer resultado derivado desta.

Leprosy: A clinical review.

Autores: Andreia P. Gomes, Paulo Sergio B. Miguel, Francisca B. Martins Mafra, Ana Claudia L. de Moura and Luciene M. Braga
Data: July-Dec 2021

De: Brazilian Journal of Health and Biomedical Sciences(Vol. 20, Issue 2)
Editora: Universidade do Estado do Rio de Janeiro- Uerj

Tipo de documento: Article

Extensão: 5.818 palavras

DOI: <http://dx.doi.org/10.12957/bjhbs.2021.63968>

Resumo:

Leprosy is a chronic infectious disease, caused by *Mycobacterium leprae*. It has great historical importance and is responsible for high rates of infected people all over the world, Brazil being the second country in number of cases, only behind India. The clinical manifestations of the disease depend on the host's immune response, and it has the potential to affect practically all organs and systems, although it mainly affects the skin and peripheral nerves, and may, above all, present periods of aggravation, which are called reactions. Thus, it is characterized as a disease of incapacitating character, which can bring irreparable physical deformities, presenting a great impact on the physical, social, and mental health of the patient. In this review we discuss the main aspects involving the condition of neglected disease, especially the epidemiology, classifications, clinical picture, complications, diagnosis, treatment, and care for prevention.

Keywords: *Mycobacterium leprae*; Leprosy; Epidemiology.

Introduction

Leprosy is a chronic, neglected infection of clinical and historical importance, caused in most cases by *Mycobacterium leprae*. The disease is prevalent in Asia, Africa, and the Americas, especially in low- and middle-income countries. The number of annual reports exceeds 200,000 cases, so leprosy remains a major public health problem in endemic countries. *M. leprae* is also the cause of leprosy neuropathy, one of the most common infectious neuropathies worldwide. (1)

The various clinical manifestations of leprosy result from variations in the tissue response of genetically predisposed individuals to the presence of the etiologic agent and depending on the immune status of the patient, the bacteria die or multiply. (2) Disease transmission occurs via the respiratory route between infected and healthy individuals. (3) In addition, *M. leprae* DNA has been detected in soils near animal and human sources, indicating that such environments may represent temporary reservoirs of the bacterium, paving the way for studying other forms of transmission. (4)

Since leprosy is a neglected disease and Brazil is an important endemic area, it is necessary to conduct studies in order to understand the ongoing impact of the disease on affected individuals. (3) Additionally, developing, standardizing and deploying more accurate diagnostic tests in order to detect and treat it as early as possible and avoid the resulting disabilities is essential, especially among the most marginalized and less socially and economically advantaged individuals. (5) Therefore, important and current information about leprosy is presented here, with emphasis on the etiological, epidemiological, clinical and classification aspects, the complications, diagnosis, treatment and prevention of leprosy, which can help in the development of

treatment plans and rehabilitation of patients.

Etiologic agent

The genus *Mycobacterium* consists of gram-positive Actinobacteria with high GC (guanine cytosine) content, which includes both non-pathogenic and pathogenic species. (6) *M. leprae* is an obligate intracellular pathogen, not grown on artificial media, (7) but grown *in vivo* in experimental animals, (8) which until 2008 was the only known etiological agent of leprosy. Another agent of the disease is *M. lepromatosis*, described in 2008 in Mexico in patients with fatal disseminated virchowian leprosy, and with DNA sequence distinct from *M. leprae*. (9) However, despite this considerable genetic divergence between these species, the clinical manifestations and treatment are similar, and it is only possible to distinguish them using molecular tests. (10) *M. leprae* multiplies more slowly than *M. lepromatosis*, with a generation time of about 12 to 13 days, (11) which implies a long incubation period, which can range from two to 10 years after infection, depending on the form of the disease. (12) *M. lepromatosis* is predominant in cases of diffuse lepromatous leprosy (DLD), a severe form of the disease, endemic in Costa Rica and Mexico. (13) Molecular epidemiological studies about leprosy are useful to understand the focal transmission and the global spread of strains. (14) They can help to know transmission and to identify individuals who are at risk of contracting the disease. (15) In addition, molecular epidemiology allows a more adequate understanding of the evolution of the pathogenic strain associated with ancient human migrations and phylogeographic perceptions involving the spread of diseases worldwide. (10)

Globias, clusters of *M. leprae* adhered and bound by gelatinous substance, obtained from the lesions of untreated multibacillary patients, can be observed by light microscopy after Ziehl-Neelsen staining. (16) *M. leprae* shows tropism for Schwann cells, keratinocytes, and macrophages (17) and a predisposition to spread more efficiently in cooler regions of the body, such as the nerves near the skin surface, the skin itself, and the membranes of the upper respiratory tract. (11)

Humans are the main carriers of the infection, excluding the American continent, where nine-banded armadillos (*Dasypus novemcinctus*) also function as zoonotic reservoirs of *M. leprae*. (7) Indeed, in the United States of America, leprosy is recognized as a zoonosis, where contact with armadillos represents a significant risk for developing the disease. (18) In other countries, however, the role played by them is being investigated as a real possibility, given the reports of infected nine-banded armadillos in countries such as Colombia, Mexico, Argentina, French Guiana and even Brazil. (10) The presence of *M. leprae* in soils near animal and human activities has also been reported, (4) and the fact that bacilli remain viable inside amoebas for up to 35 days, even without replicating, (19) may be an indication of the contribution of these free-living protozoa in leprosy transmission. On the other hand, the detection of *M. lepromatosis* in red squirrels (*Sciurus vulgaris*) in Scotland, Ireland and England with lesions like those seen in leprosy, (10) allows us to question whether these animals were reservoirs of the pathogen and the possibility of contributing to the disease cycle.

In fact, the most common route of transmission results from contact with droplets released from the upper airways of individuals with multibacillary (MB) leprosy, (20) and more rarely through the skin or by vertical transmission. (7) However, the possibility of zoonotic infection is considered a challenge to the World Health Organization (WHO) paradigm when considering leprosy elimination, which includes strategies based only on interrupting transmission between individuals, excluding any approach involving zoonotic transmission. (7)

Close and prolonged contact, especially with multibacillary patients, especially men, individuals older than 60 years or in situations of social vulnerability is another factor that favours contagion and transmission of the disease. (20) Additionally, susceptibility to the bacillus depends on the immunosuppression, immunodeficiency and genetic predisposition of individuals. (16)

Epidemiology


Leprosy is prevalent in tropical and subtropical countries and is more common in developing countries due to its association with socioeconomic vulnerability indicators. (21) Although the prevalence of the disease has been decreasing since the institution of multidrug therapy in the 1980s, an important number of cases is described in many countries in the Americas, Africa, Southeast Asia, the Eastern Pacific and the Western Mediterranean. (3)

The disease is reported in about 143 countries, with 214,783 new cases, an average of 2.9 cases per 100,000 inhabitants. In Brazil, specifically, this rate is much higher (12.2/100,000 hab), second only to India and followed by Indonesia, Bangladesh and Nigeria, (21) with reported 80% cases. (3) In Latin America, Brazil accounts for over 90% of cases. (22) Worldwide, about 7.6% of new leprosy cases occur in children, and it can be interpreted that the disease has continuous active transmission in some communities. (10)

The most of cases in Brazil are described in males, people of colour, and lower education, coming from the Midwestern (37.27/100,000 inhab.) and Northern (34.26/100,000 inhab.) regions of the country, and at a lower frequency in the Southern

(3.75 per 100,000 inhabitants) and Southeastern (5.31 per 100,000 inhabitants) regions. (16) Data from molecular epidemiology have shown the presence of several distinct strains of *M. leprae* circulating in the country, with a higher prevalence of two: SNP type 4 in the Southeast and SNP subtype 3I in the Northeast. Subtype 3I, more common in medieval Europe, is likely derived from multiple introductions by successive waves of colonization. (23)

Cases of leprosy (LLD) caused by *M. lepromatosis* are endemic to Costa Rica and Mexico, with smaller numbers recorded in Canada, Singapore, Brazil and Myanmar. Furthermore, this etiologic agent is also responsible for other clinical forms of the disease, which may coexist with *M. leprae* in these areas. (13)



Madrid classification

The Madrid classification (1953) considers the tendency of leprosy to evolve naturally towards one of two stable and diametrically opposed poles--Virchowian (VV) and tuberculoid (TT)--from two unstable groups --indeterminate (I) and dimorphic (D, or borderline, B), (Figure 1) that are characterized by specific signs and symptoms (Table 1). This is the most widely used classification in Brazil and is included in the notification forms of the Sistema de Informacao de Agravos de Notificacao (SINAN). (16) In this classification, the pure neuritic type is included in the indeterminate, lepromatous and tuberculoid groups, which is considered a problem. (2)

Ridley & Jopling classification

The Ridley and Jopling (25) classification is based on the spectrum of clinical, histopathological and immunological features of the individuals. In this model, dimorphic leprosy is categorized into the Virchowian (LL) and tuberculoid (TT) forms at the ends of the spectrum and cases showing characteristics intermediate between the extremes (Figure 2). Thus, the dimorph group is subdivided into three subgroups: dimorphic-virchowian (DV), dimorphic-dimorphic (DD), and dimorphic-tuberculoid (DT). (26) This classification has been widely accepted, as is based on bacteriological, immunological, histopathological and clinical features of leprosy. However, it does not consider neuritic leprosy in the spectrum. (2)

In Ridley and Jopling's Classification, (25) the indeterminate form marks the beginning of the disease, and most cases tend to evolve spontaneously to cure. However, evolution to polarized or dimorphic forms is possible, which takes an average of five years, and may be earlier for the TT form. The lesions are typically characterized by a hypochromic macula with imprecise borders and the presence of sensitivity disturbances, areas of hypoor anaesthesia. Usually few or single lesions are present, anhidrosis and/or hair loss is possible, and there is no peripheral nerve involvement. The smear is negative and the Mitsuda reaction positive or negative, which may indicate a tendency to evolve into the extreme forms. Histopathological findings include focal lymphohistiocytic, perivascular, perianaxial, and perineural inflammatory infiltrates, but the diagnosis of leprosy is only made by the visualization of bacilli within the nerve filaments. Nevertheless, when the Mitsuda test is negative, this form is considered Paudbacillary (PB) for treatment purposes. (16)

The tuberculoid-tuberculoid (TT) form is more benign, due to the more effective cellular immune response against the bacillus. The lesions typically show as a macula or plaque, erythematous and/or hypochromic, with well-defined and slightly elevated borders, with reduced or lost sensation. The lesion is usually single or in small numbers (usually no more than three lesions). Symmetric nerve trunk involvement occurs, although asymmetric involvement is possible and may be the only clinical manifestation of the disease. In the area near the plaque lesion, neural thickening of the underlying nerve trunk ("Racket Sign") may occur, (27) and in the lesions themselves or in the nerve tracts with total loss of sensation, anhidrosis and/or alopecia. (16)

Alteration in sensitivity tends to follow an evolutionary order: (1) altered thermal sensitivity; (2) painful and (3) tactile. Histopathological findings include the observation of cohesive granulomas, consisting of epithelioid histiocytes and, occasionally, multinucleated giant Langhans-like cells, which is attributed to a more effective Th1 response. The granulomas tend to elongate, accompanying the vessels, nerves, and sweat glands, circumscribed by lymphocyte sheaths, with rare or absent bacilli. In addition, granulomas may permeate and destroy neural filaments. The smear is negative and the Mitsuda test positive. Additionally, the nodular form of childhood can occur, which is a variation of the T form. It affects children aged 1 to 4 years who have household contact with MB adults, forming erythematous-brown papular or nodular lesions on the face and limbs, usually single or small in number, without neural involvement, and regressing, leaving an area of atrophy. On histopathological examination, well-organized tuberculoid granulomas are observed. (16)

Another extreme form, Virchowian-virchowian (VV) is the most severe, due to the deficient cellular immune response against the bacillus, which results in multiplication of the bacteria within macrophages and Schwann cells. The patient with this null response is called anergic and presents diffuse tegumentary infiltration, abundant lesions in plaques, tubercles and nodules (leprosy), erythematous to violaceous in color, which can also affect the oral mucosa. In this form, the leonine facies may develop, characterized by auricular involvement with infiltration of the face (which gives the appearance of thickened skin and an enlarged nose) and superciliary and ciliary madarosis--with hair maintenance. Given the absence of cellular immune response, the bacilli become free to disseminate through the lymphatic and blood routes and reach other organs such as the lymph nodes, spleen, liver, adrenals, larynx, bone marrow, testes, synovium, and eyeball. The more common features of the TT form--involving sensory disturbances and peripheral neural involvement--are present, but in a later and less marked form. There are two main variants: the histoid virchowian variant, which is defined by the formation of keloid-like lesions and may be sulfone resistant; and the Lucio variant, in which there is typically diffuse infiltration of the entire integument, making lesions more difficult to visualize. The Pike phenomenon can be frequent in these cases and is characterized by the formation of highly contagious necrotic ulcers. In addition, auto aggressive leprosy disease can appear in patients with the VV or, rarely, the DV form, and occurs given the development of autoimmunity --which explains the differential diagnosis of the condition with systemic lupus or rheumatoid arthritis. It is characterized by a febrile picture, anorexia and weight loss, arthralgia and neuralgia, which is succeeded by internal organ involvement and type II leprosy reactions, or even necrotizing vasculitis. (16,28)

The histopathological findings include many macrophages with ample or vacuolated cytoplasm, indicating that the bacilli were phagocytosed but could not be destroyed (since the Th1 response failed), and plasma cells, which are responsible for humoral immunity, with sparse lymphocytes. The epidermis is separated from the inflammatory infiltrate by the fibrous band of collagen known as the Unna band. The neural filaments are preserved, although they are surrounded by numerous bacilli and macrophages. Over time, the macrophages become foamy or vacuolated (Virchow cells), due to the accumulation of bacilli within them. In addition, mycobacteria can also be found in large numbers in blood vessels, in the piloerector muscles, and in the root sheaths of hair follicles. The IB can range from 5+ to 6+, the Mitsuda reaction is negative, and the smear is positive. Operationally classified as MB. (16,28)

The dimorphous-tuberculoid (DT), dimorphous-dimorphous (DD) and dimorphous-virchowian (DV) forms (Table 2) show immunological instability, with varied clinical presentations, which may approach the extreme poles, tuberculoid or virchowian. Skin lesions are varied, presenting as erythematous, erythematohypochromic, brownish, ferruginous, infiltrative, edematous, shiny plaques or nodules, with altered or complete loss of sensation. Neurological involvement is frequent and may be more extensive and asymmetric, and neuritis may occur. In addition, this form is more prone to reactionary episodes (type I and II flare-ups), which can progress and lead to disability. Finally, the patient's skin is usually dry and anhydrotic, which predisposes it to cracks and ulcers. They are operationally classified as MB. (16,29)

Operational classification

The operational classification proposed by the WHO in the late 1990s divides the forms into paucibacillary (few bacilli--PB) and multibacillary (many bacilli --MB) and is used for treatment purposes. PB cases are those that result in up to five skin lesions, affect only one or none of the peripheral nerves, and are always smear negative. Patients with MB have more than five skin lesions and/or involve more than one peripheral nerve, and the smear may be negative or positive. (30) In Brazil, the Ministry of Health in 2002 guided the counting of the number of lesions as sufficient clinical criteria for operational classification, given the difficulty in diagnosing the neural thickening criterion, dependent on the assessment of examiners, and more difficult for those with less experience. (16)

Complications of leprosy

These are clinical manifestations of leprosy that do not fit into the typical categories of the disease such as primary nerve lesion and reaction episodes. Primary neural leprosy is a public health problem, especially in developing countries. It is a clinical form characterized by the absence of skin lesions and negative skin smears, so the diagnosis is based mainly on complementary tests, especially electroneuromyography, nerve biopsy, serology and molecular analyses. These more advanced tools are not always available in health services, even in those considered reference in the treatment of the disease. (31)

The most typical manifestations of primary nerve lesion involve the asymmetric involvement of nerves (multiple mononeuropathy), and the most affected nerves are the ulnar, median, radial, posterior tibial, and common peroneal nerves. The ulnar nerve lesion alone or together with the median nerve leads to the clinical sign of "claw hand", and if there is a radial nerve lesion, there is also the "fallen hand" deformity. Lesions in the tibial trunk, on the other hand, result in loss of sebaceous gland innervation and sensitivity in the plantar region, making the skin drier, more fragile, and susceptible to traumas that predispose to plantar perforating disease. The involvement of the common peroneal nerve makes it impossible to elevate the foot, making walking difficult, causing the "fallen foot" sign. In the face, lagophthalmos may occur, due to injury to the zygomatic branch in the facial nerve. (16) Nonspecific symptoms may include intense burning pain, paraesthesia, thermal and painful anaesthesia, hypohidrosis, motor losses, soft tissue involvement, arthritis in small and large joints, nerve thickening, and pain on palpation. The various differential diagnoses include rheumatoid arthritis, spondyloarthropathies, collagenosis,

vasculitis, diabetes, hypothyroidism, tumours, AIDS, syphilis, traumatic causes. (32)

Ocular complications are important problem in Brazil. Multibacillary patients had a higher risk of developing lagophthalmos, that does not revert with the treatment and was associated with punctate keratitis, cataracts, uveitis and a higher risk of reduced visual acuity. (33) These ocular changes were frequently associated with neural disease and all patients must be evaluated by a specialist in ocular disease. These complications indicate the need of complete assistance to patients even after the resolution of the disease. (34)

Reaction episodes

Table 1. Main characteristics of the clinical forms of leprosy according to the Madrid classification

Form	Signs and symptoms	Mitsuda	Bacilloscopy	Peripheral neural involvement	Leprosy reaction
I	Hypochromic spot or hypoesthetic area, imprecise limits	Positive or negative	Negative	Absent	Absent
T	Erythematous or erythematohypochromic plaque, anesthetic, defined borders	Positive	Negative	Localized, close to the skin lesion	Absent
D	Hypochromic patches, erythematous plaques, anesthetic areas, foveolar lesions	Positive or negative	Positive or negative	It can be intense, early, multiple	Reaction outbreak type 1 (all) or type 2 (positive sputum smear)
V	Erythematoviolaceous plaques, livedo reticularis, nodules, infiltration, madarosis, xeroderma	Negative	Positive	Late, moderate, diffuse	Reactionary outbreak type 2

Source: Lyon S & Grossi MAF. Leprosy. Rio de Janeiro: Medbook, 2013 (adapted).²⁴

Leprosy, characterized by a chronic course, can present reactionary outbreaks, i.e., acute or subacute manifestations due to immunological hyper-reactivity to *M. leprae* antigens. (35) Immunological events affect between 8 to 33% of patients, (36) with pictures that can be triggered by situations that alter the immune system: infections, vaccination, use of iodinated drugs, pregnancy and puerperium, physical, surgical or psychological stress situation or trauma. (35) During the natural evolution of the disease, concomitant to treatment or even after cure, reactions can show specific complications, which result in sequelae if not treated properly and quickly. Complications in the ocular apparatus cause scleritis, uveitis, iritis and iridocyclitis, with irreversible lesions and even blindness. (16)

Reaction episodes can be subdivided into type 1 reactions (T1R), with a predominance of high levels of tumour necrosis factor alpha (TNF-[alpha]), interferon-gamma (IFN-[alpha]), interleukin-17 (IL-17) and chemokine 10, and erythema nodosum leprosum (T2R) (Antunes et al., 2020). Type 1 reaction is more common in paucibacillary patients with the tuberculoid or dimorphic forms of the disease. (37) It usually starts before treatment with multidrug therapy (MDT) or within the first six months, but it can also be the first clinical manifestation of the disease. It is characterized by the appearance of new lesions or the re-aggravation and exacerbation of old lesions, with an erythematous and edematous appearance, and the formation of infiltrates or nodules that may develop into ulcers. Increased hypo- or anesthetic areas and neuritis, involving shock and/or pain in the neural tract, are common. Associated factors are edema of the hands and feet and the abrupt onset of "claw hand" and "foot drop," given the most common involvement of the ulnar, median, fibular, and tibial nerves. (17)

More recently, studies have suggested SARS-COV-2-induced hyperinflammation as the cause of mortality in leprosy patients. This is because the presence of the virus can trigger cytokine storm syndrome and patients express pro-inflammatory profile in the blood plasma with IL-2, IL-7, TNF-[alpha], among others. (36)

Systemic involvement is not frequent, being restricted to the most severe cases, with fever, malaise, fatigue and anorexia. Hematological tests generally show no alterations, and when they do occur, the most common is leucocytosis. It is noteworthy that the reverse reaction must be differentiated from the relapse; the outbreak has a sudden and unexpected evolution, with old lesions reaggravated, and usually appears during treatment or up to five years after its end and responds well to therapy using corticoids. The relapse is rarer, has a slow and insidious onset, the old lesions are usually imperceptible, usually occurs five years after the end of multidrug therapy and does not respond well to corticotherapy. (17) Erythema nodosum leprosum is described in multibacillary patients, in the VV and some DV forms, (37) usually during or after treatment with MDT, but it can also be the first manifestation of the disease. It is an immune hyper-reactivity, which occurs in the blood and tissues, mainly in the skin, kidneys and joints, (36) caused by the deposition of immunocomplexes, which generate an intense inflammatory reaction. This clinical manifestation is more severe and can leave irreversible sequelae. Erythema nodosum leprosum is characterized by the sudden appearance of erythematous, subcutaneous, painful nodules, can evolve to vesicles, pustules, ulcers, and necrosis in severe cases, mainly on the face and upper and lower limbs. There is also a systemic involvement, and the occurrence of hepatosplenomegaly, glomerulonephritis, edema of the extremities--which can lead to epistaxis, orchitis, lymphadenitis, vasculitis, iridocyclitis, periostitis, nasal obstruction, scleritis, and episcleritis--and the gradual involvement of the nerve trunks is possible. The main associated symptoms are fever, asthenia, myalgia, nausea, joint pain, and weight loss. (36) Neuritis, when it occurs is less intense compared to that which occurs in type I reaction. Acute, diffuse inflammation of the soft tissues of the feet and hands cause serious edema and pain, are referred to as "reaction hands" or "reaction feet," and can leave sequelae. Erythema polymorphous may also be part of this leprosy reaction and is represented by erythematous,

swollen, circular skin plaques that may resemble a target. Regarding laboratory tests, leucocytosis can occur, with deviation to the left, neutrophilia, platelets, increased immunoglobulins and proteinuria. (16) Regarding neutrophilia, in the pulmonary capillaries, SARS-COV-2 can trigger an extensive neutrophil infiltration, in severe patients. Similarly, patients with erythema nodosum leprosum, show intense perivascular infiltrate of neutrophils in the dermis, which makes some researchers argue that neutrophils, influenced by the presence of the virus, is related to the development of ENL (erythema nodosum leprosum) in leprosy patients. (36)

Some complications and sequelae of this reaction are in the case of acute orchitis, which can lead to testicular atrophy and the later appearance of gynecomastia. In addition, amyloidosis can be a complication of the VV form, with type 2 reactions. The differential diagnosis is sepsis. (16)

Diagnostics

The diagnosis of leprosy is essentially clinical and epidemiological, but complementary tests contribute to the clinical classification. Early diagnosis and specific treatment are essential to reduce sequelae, complications and to prevent transmission of the disease. In Brazil, the diagnosis is defined if the patient presents skin lesion with altered sensitivity or nerve involvement with neural thickening or positive bacilloscopy. (38)

The polymerase chain reaction (PCR) has high sensitivity and specificity; more than 90% and 100%, respectively. (11) The high cost restrict its use to research centres in Brazil. (24)

ELISA or rapid immunochromatographic tests show low sensitivity, and they are not recommended, especially for PB patients, who are mostly seronegative. (12)

Treatment

The treatment of leprosy is outpatient and should be carried out in basic health units, with multidrug therapy (MDT), recommended by WHO since 1982. MDT is a combination of rifampicin, dapsone and clofazimine or rifampicin and dapsone, used to treat patients with MB (Table 3) and PB (Table 4), respectively. (39) With treatment, transmission ceases and cure is assured, (11) however, in fertile women there may be interaction between rifampicin and contraceptives. (40)

Paucibacillary cases, in which there is a single lesion on the skin, are treated with the ROM scheme in a single dose--rifampicin at a dose of 600 mg, ofloxacin at a dose of 400 mg, and minocycline at a dose of 100 mg. In special situations where adherence to standard treatment is difficult, such as in mental disorders and alcoholism, monthly supervised doses can be used, six doses for PB and 24 for MB. (16)

In children and adults with a body mass of less than 30kg, the doses are adjusted according to the patient's mass (Table 5).

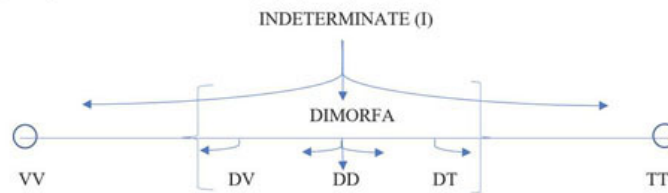
The introduction of World Health Organization (WHO) multidrug therapy (MDT) has played a pivotal role in achieving the epidemiological target of elimination of leprosy as a public health problem. (41) However, a subset of MB patients who not responding satisfactorily (clinically and microbiologically) to the current fixed duration (FD) of WHO-MDT-MB regimen (MBR) is observed. In Brazil, the drug treatment currently offered by the Sistema Unico de Saude (SUS) combines three drugs: rifampicin, dapsone and clofazimine. In cases of resistance to rifampicin, the Ministry of Health recommends the exchange for minocycline or ofloxacin. For cases that, however, there is resistance to treatment, there has been the therapeutic option of using clarithromycin since December of 2020. (42)

Narang et al, observed in India in patients who are "nonresponsiveness" to conventional treatments after anti-leprosy therapy comprised minocycline 100 mg/ day, clofazimine 50 mg/day, and ofloxacin 400 mg/ day for 6 months (intensive phase), and ofloxacin 400 mg/day and clofazimine 50 mg/day for the next 18 months (maintenance phase). They conclude that treatment is safe and effective in the management of MB leprosy patients who are nonresponsive to 12 months of WHO-MDT-MBR. (41)

Prevention and control

The prevention and treatment of leprosy and reaction states seek to prevent the transmission of the disease, the onset of disabilities and permanent physical impairments, as well as to avoid further emotional and socioeconomic damage to the patient. (16) Thus, to reduce the disease burden, it is necessary to strengthen government control, coordination and partnership, combat leprosy and its complications, combat discrimination and promote social inclusion. Emotional support by family, community and health workers is essential, but no less important than social and financial support services. (21)

Figure 2. Spectrum of clinical forms of leprosy by Ridley and Jopling classification



Source: The authors (2021).

The main way to prevent sequel of the disease is early diagnosis and immediate initiation of treatment. (38,43) For this, it is necessary to systematically search for patients in endemic areas, investigate household or close contacts of the patient and offer free, immediate and specific treatment. (44)

Smith (45) observed that the use of chemoprophylaxis with dapsone and acedapsone is effective in reducing the incidence of leprosy, particularly among home contacts, who have a higher risk of developing disease. Chemoprophylaxis for contacts is promising, and the drug of choice is now the rifampicin, (46) which can prevent up to 57% of cases in the first two years. (47)

Vaccination with BCG (Bacille de Calmette et Guerin), although specific for tuberculosis, show efficacy against leprosy and is indicated for contactantes intradomiciliary. (48) Nevertheless, there are two vaccines (Mycobacterium indicus pranii (MiP) and LepVax) under study that may standardize post-exposure prophylaxis. (46,49)

DOI: 10.12957/bjhbs.2021.63968

References

- (1.) Hess S, Rambukkana A. Cell biology of intracellular adaptation of Mycobacterium leprae in the peripheral nervous system. *Bacteria and Intracellularly*. 2020;227-245. <https://doi.org/10.1128/microbiolspec.BAI-0020-2019>.
- (2.) Arif T, Dorjay K, Adil M, et al. Classification of leprosy-From past to present. *Journal of Pakistan Association of Dermatology*. 2018; 28(1):95-99.
- (3.) Sarode G, Sarode S, Anand R, et al. Epidemiological aspects of leprosy. *Disease-a-Month*, 2020: 100899. <https://doi.org/10.1016/j.disamonth.2019.100899>
- (4.) Tio-Coma M, Wijnands T, Pierneef L, et al. Detection of Mycobacterium leprae DNA in soil: multiple needles in the haystack. *Scientific reports*. 2019;9(1):1-7. <https://doi.org/10.1038/s41598-019-39746-6>
- (5.) Steinmann P, Dusenbury C, Addiss D, et al. A comprehensive research agenda for zero leprosy. *Infectious Diseases of Poverty*. 2020;9(1):1-7. <https://doi.org/10.1186/s40249-02000774-4>.
- (6.) Pedelacq JD, Nguyen MC, Terwilliger TC, et al. A Comprehensive Review on Mycobacterium tuberculosis Targets and Drug Development from a Structural Perspective. *Structural Biology in Drug Discovery: Methods, Techniques, and Practices*. 2020:545-566. DOI: 10.1002/9781118681121.ch23
- (7.) Maymone MB, Laughter M, Venkatesh S, et al. Leprosy: Clinical Aspects and Diagnostic Techniques. *Journal of the American Academy of Dermatology*. 2020;83:1-13. <https://doi.org/10.1016/j.jaad.2019.12.080>
- (8.) Shepard CC. The experimental disease that follows the injection of human leprosy bacilli into footpads of mice. *Journal of Experimental Medicine*. 1960;112(3):445-54. <https://doi.org/10.1084/jem.112.3.445>
- (9.) Sharma R, Singh P McCoy RC, et al. Isolation of Mycobacterium lepromatosis and Development of Molecular Diagnostic Assays to Distinguish Mycobacterium leprae and M. lepromatosis. *Clinical Infectious Diseases*. 2020;71(8):e262-e269. <https://doi.org/10.1093/cid/ciz1121>
- (10.) Avanzi C, Singh P Truman RW, et al. Molecular epidemiology of leprosy: An update. *Infection, Genetics and Evolution*,

(11.) Bhandari J, Awais M, Gupta V. Leprosy (Hansen Disease). StatPearls [Internet]. 2020. Available from: <https://www.ncbi.nlm.nih.gov/books/NBK559307/>

(12.) Reibel F, Cambau E, Aubry A. Update on the epidemiology, diagnosis, and treatment of leprosy. *Med Mal Infect.* 2015; 45:383-93. <https://doi.org/10.1016/j.medmal.2015.09.002>

Table 2. Characteristics of the dimorphic - tuberculoid (DT) form according to the Ridley and Jopling Classification (1962)

	Dimorphic - tuberculoid (DT)	Dimorphic - dimorphic (DD)	Dimorphic - virchowian (DV)
"Form"	Unstable; tends to the TT extreme.	Unstable; tends to one of the extremes, TT or VV.	Unstable, tends to the extreme VV.
Characterization of the lesions	Cutaneous similar to the TT form. They are usually satellites, smaller and more numerous around the main lesion.	Foveolar - eithymatopigmentary plaques, edematous; with a depressed nucleus, hypo- or normochromic or hypo- or anesthetic.	Cutaneous similar to the VV form, with nodules and infiltrations; more violaceous coloration, mainly on the face and in the ear pinnae. It may show as disseminated.
Histopathological findings	Milder, extensive granulomas limited to the dermis, with the formation of a narrow collagenous fibrous band just under the epidermis (Unna's band or Grenz's zone). Langerhans-type multinucleated giant cells in varying numbers. Thickening of the nerves tends to be irregular, and usually the nerve filaments are more preserved.	Traces of loose, diffusely distributed granulomas, with the presence of clear cytoplasmic epithelioid cells. Absence of multinucleated giant cells. Diffusely distributed mimicked lymphocytes in number. Neural fillets are mostly easy to identify and many show proliferation of Schwann cells. Excessive interstitial edema occurs in the dermis.	Moderate activation of macrophages. Presence of numerous lymphocytes compared to the VV form, forming poorly defined granulomas. Presence of plasma cells can occur. Easily identifiable neural filaments that show proliferation of Schwann cells or perineural fibroblasts, ("onion skin" appearance).
Mitsuda's reaction	Positive	Generally negative	Negative
Bacilloscopy	Negative	It can be positive	Positive
IB	Can range from 0 to 2+	Can range from 3+ to 4+	Can range from 4+ to 5+
Operational Classification	Multibacillary	Multibacillary	Multibacillary

Source: Ridley DS, et al. (1966).²⁵ (Adapted); Brazil, Ministério da Saúde (2019).¹⁸

(13.) Grayson, W. An update on cutaneous infections. *Diagnostic Histopathology.* 2020;26(3):107-113. <https://doi.org/10.1016/j.mpdhp.2019.12.002>

(14.) Mathema B, Kurepina NE, Bifani PJ, et al. Molecular epidemiology of tuberculosis: current insights. *Clinical microbiology reviews.* 2006;19(4), 658-685. <https://doi.org/10.1128/CMR.00061-05>

(15.) Das M, Diana D, Wedderburn A, et al. Molecular epidemiology and transmission dynamics of leprosy among multicase families and case-contact pairs. *International Journal of Infectious Diseases.* 2020;96:172-179. <https://doi.org/10.1016/j.ijid.2020.04.064>

(16.) Brasil. Ministerio da Saude. Guia de Vigilancia em Saude 3. ed. Brasilia. 2019; p 294-325.

(17.) White C, Franco-Paredes C. Leprosy in the 21st century. *Clinical Microbiology Reviews.* 2015;28(1):80-94. <https://doi.org/10.1128/CMR.00079-13>

(18.) Truman R, Singh P Sharma R, et al. Probable Zoonotic Leprosy in the Southern United States. *N Engl J. Med.* 2011; 364:1626-1633. DOI: 10.1128/CMR.00079-13

(19.) Chavarro-Portillo B, Soto CY, Guerrero MI. Mycobacterium leprae's evolution and environmental adaptation. *Acta Tropica.* 2019;197:105041. <https://doi.org/10.1016/j.actatropica.2019.105041>.

(20.) Bratschi MW, Steinmann P, Wickenden A, et al. Current knowledge on Mycobacterium leprae transmission: a systematic literature review. *Leprosy Review.* 2015;86(2):142-55.

(21.) World Health Organization. Global Leprosy Strategy 2016-2020: Accelerating towards a world without leprosy. Geneva: WHO/SEARO, 2016. 36 p.

(22.) World Health Organization. Weekly epidemiological record. 2019 30 Aug; 94(35/36):389-412.

(23.) Benjak A, Avanzi C, Benito Y, et al. Highly reduced genome of the new species *Mycobacterium uberis*, the causative agent of nodular thelitis and tuberculoid scrotoitis in livestock and a close relative of the leprosy bacilli. *MSphere*. 2018;3(5):1-11. 10.1128/mSphere.00405-18

(24.) Lyon S, Grossi MAF. *Leprosy*. Rio de Janeiro: Medbook, 2013.

(25.) Ridley DS, Jopling WH. Classification of leprosy according to immunity. A five group system. *International Journal of Leprosy*. 1966;34:255-273.

(26.) Lastoria JC, Abreu MAMMD. Leprosy: review of the epidemiological, clinical, and etiopathogenic aspects-part 1. *Anais Brasileiros de Dermatologia*. 2014;89(2):205-218. <https://doi.org/10.1590/abd1806-4841.20142450>

(27.) Brandao LSG, Marques GF, Barreto JA, et al. Tuberculoid leprosy presenting as a "racket" lesion. *Anais Brasileiros de Dermatologia*. 2015;90(3):420-422. 10.1590/abd18064841.20153401

(28.) Rodrigues ACS, Quintella DC, Rodrigues FT, et al. Lepromatous Leprosy: Report of a Case of the Histiocytic Symile Type. *Journal of the Portuguese Society of Dermatology and Venereology*. 2019;77(1):73-76. <https://doi.org/10.1186/s42047-019-0051-x>

(29.) Kumar B, Uprety S, Dogra S. Clinical diagnosis of leprosy. *International Textbook of Leprosy*. 2017. 24p. Disponível em: https://www.internationaltextbookofleprosy.org/sites/default/files/ITL_2_1%20FINAL_1.pdf

Adult	Rifampicin (RFM): monthly dose of 600 mg (2 capsules of 300 mg) with supervised administration.
	Dapsone (DDS): supervised monthly dose of 100 mg and a self-administered daily dose of 100 mg.
	Clofazimine (CFZ): monthly dose of 300 mg (3 capsules of 100 mg) with supervised administration and a daily self-administered dose of 50 mg.
Child	Rifampicin (RFM): monthly dose of 450 mg (1 capsule 150 mg and 1 capsule 300 mg) with supervised administration.
	Dapsone (DDS): supervised monthly dose of 50 mg and a self-administered daily dose of 50 mg.
	Clofazimine (CFZ): monthly dose of 150 mg (3 capsules of 50 mg) with supervised administration and a 50 mg dose self-administered every other day.

Source: Brazil, Ministry of Health (2019).³⁵

(30.) World Health Organization. Expert committee on leprosy. *World Health Organ Tech Rep Ser*. 1998;874:1-43.

(31.) Santos DFD, Mendonga MR, Antunes DE, et al. Revisiting primary neural leprosy: clinical, serological, molecular, and neurophysiological aspects. *PLoS Negl Trop Dis*. 2017;11(11):e0006086. <https://doi.org/10.1371/journal.pntd.0006086>

(32.) Freitas RCSD, Pereira CAZ, Muri NT, et al. Primary neural leprosy mimicking rheumatological disorders. *Revista da Associacao Medica Brasileira*. 2019;65(6):767-770. <https://doi.org/10.1590/1806-9282.65.6767>

(33.) Cohens JM. Hanseníase ocular: uma abordagem histórica. *Arquivos Brasileiros de Oftalmologia*. 2009;72(5):728-33. <https://doi.org/10.1590/S0004-27492009000500027>

(34.) Araujo AERA, Aquino DMC, Goulart IMB, et al. Complicações neurais e incapacidades em hanseníase em capital do nordeste brasileiro com alta endemicidade. *Revista Brasileira de Epidemiologia*. 2014;17(4):899-910. <https://doi.org/10.1590/1809-4503201400040009>

(35.) Azulay RD, Azulay DR, Azulay-Abulafia L. *Dermatology*. Rio de Janeiro: Ed. 2017.

(36.) Antunes DE, Goulart IMB, Goulart LR. Will cases of leprosy reaction increase with COVID-19 infection. *PLoS neglected tropical diseases*. 2020;14(7), e0008460. <https://doi.org/10.1371/journal.pntd.0008460>

(37.) Akpolat ND, Akkus A, Kaynak E. An update on the epidemiology, diagnosis and treatment of leprosy. In: *Hansen's Disease-The Forgotten and Neglected Disease*. IntechOpen, 2018. Disponível em: <https://www.intechopen.com/books/hansen-s-disease-the-forgotten-and-neglected-disease/an-update-on-the-epidemiology-diagnosis-and-treatment-of-leprosy>.

- (38.) Brasil. Ministerio da Saude. Guia Pratico em hanseniose. 1. ed. Brasilia, 2017.
- (39.) World Health Organization. Weekly Epidemiological Record. 2021;96:01-02.
- (40.) Lyon S, Grossi, MAF. Diagnosis and treatment of leprosy. In: Leprosy advances and challenges. 2014; p.141-169.
- (41.) Narang T, Bishnoi A, Dogra S, et al. Alternate Anti-Leprosy Regimen for Multidrug Therapy Refractory Leprosy: A Retrospective Study from a Tertiary Care Center in North India, The American Journal of Tropical Medicine and Hygiene. 2019; 100(1):24-30. <https://doi.org/10.4269/ajtmh.18-0256>
- (42.) Brasil. Coordenacao de Monitoramento e Avaliacao de Tecnologias em Saude--CMATS/CGGTS/DGITIS/SCTIE/MS. Relatório de recomendacao de medicamento no. 583. Ampliacao de uso da claritromicina para o tratamento de pacientes com hanseniose resistente a medicamentos. Brasilia, 2020.
- (43.) Bhandari J, Awais M, Robbins BA, et al. Leprosy. [Updated 2021 Jun 7]. In: StatPearls [Internet]. Treasure Island (FL): StatPearls Publishing; 2021 Jan. Available from: <https://www.ncbi.nlm.nih.gov/books/NBK559307/>
- (44.) Sarkar T, Sarkar S, Patra AC, et al. BCG vaccination: Effects on the patterns of pediatric leprosy. J Family Med Prim Care. 2020 Jul 30;9(7):3673-3676. https://doi.org/10.4103/jfmpc.jfmpc_478_20
- (45.) Smith CM, Smith WC. Chemoprophylaxis is effective in the prevention of leprosy in endemic countries: a systematic review and meta-analysis. MILEP2 Study Group. Mucosal Immunology of Leprosy. Journal of Infect. 2000;41(2):137-42. <https://doi.org/10.1053/jinf.2000.0698>.
- (46.) Schoenmakers A, Mieras L, Budiawan T, et al. The State of Affairs in Post-Exposure Leprosy Prevention: A Descriptive Meta-Analysis on Immuno- and Chemo-Prophylaxis. Res Rep Trop Med. 2020;11:97-117. <https://doi.org/10.2147/RRTM.S190300>

Table 4. Treatment regimens for paucibacillary (PB): 6 tablets in up to 9 months

Adult	Rifampicin (RFM): monthly dose of 600 mg (2 capsules of 300 mg) with supervised administration.
	Dapsone (DDS): supervised monthly dose of 100 mg and self-administered daily dose of 100 mg.
Child	Rifampicin (RFM): monthly dose of 450 mg (1 capsule 150 mg and 1 capsule 300 mg) with supervised administration.
	Dapsone (DDS): supervised monthly dose of 50 mg and self-administered daily dose of 50 mg.

Source: Brazil, Ministry of Health (2019).¹⁶

- (47.) Richardus R, Alam K, Kundu K, et al. Effectiveness of single-dose rifampicin after BCG vaccination to prevent leprosy in close contacts of patients with newly diagnosed leprosy: A cluster randomized controlled trial. Int J Infect Dis. 2019 Nov; 88:65-72. <https://doi.org/10.1016/j.ijid.2019.08.035>.
- (48.) Setia MS, Steinmaus C, Ho CS, et al. The role of BCG in prevention of leprosy: a meta-analysis. Lancet Infectious Diseases. 2006;6(3):162-70. DOI: [https://doi.org/10.1016/S1473-3099\(06\)70412-1](https://doi.org/10.1016/S1473-3099(06)70412-1)
- (49.) Mungroo MR, Khan NA, Siddiqui R. Mycobacterium leprae: Pathogenesis, diagnosis, and treatment options. Microbial Pathogenesis. 2020;104475. <https://doi.org/10.1016/j.micpath.2020.104475>

Andreia P. Gomes, [1], * Paulo Sergio B. Miguel, [2] Francisca B. Martins e Mafrá, [3] Ana Claudia L. de Moura, [4] Luciene M. Braga [3]

[1.] Departamento de Medicina e Enfermagem. Universidade Federal de Vicosa. Vicosa, Minas Gerais, Brasil.

[2.] Instituto Federal de Educado, Ciencia e Tecnologia de Roraima. Boa Vista, Roraima, Brasil.

[3.] Departamento de Medicina e Enfermagem. Universidade Federal de Vicosa. Vicosa, Minas Gerais, Brasil.

[4.] Faculdade Dinamica do Vale do Piranga. Ponte Nova, Minas Gerais, Brasil.

* Address of Correspondence: Laboratorio de Metodos Epidemiologicos e Computacionais em Saude, 3 Floor, Room 324, Campus Universitario, Vicosa, MG, Brazil. CEP: 36570-900. E-mail: andreiapgomes@gmail.com ORCID: <https://orcid.org/0000-0002-5046-6883>

Received on 08/17/2021. Approved on 10/15/2021.

Caption: Figure 1. Evolution of the clinical forms of leprosy according to the Madrid classification

Caption: Figure 2. Spectrum of clinical forms of leprosy by Ridley and Jopling classification Source: The authors (2021).

Table 1. Main characteristics of the clinical forms of leprosy according to the Madrid classification

Form	Signs and symptoms	Mitsuda	Bacilloscopy
I	Hypochromic spot or hypoesthetic area, imprecise limits	Positive or negative	Negative
T	Erythematous or erythematohypochromic plaque, anesthetic, defined borders	Positive	Negative
D	Hypochromic patches, erythematous plaques, anesthetic areas, foveolar lesions	Positive or negative	Positive or negative
V	Erythematoviolaceous plaques, livedo reticularis, nodules, infiltration, madarosis, xeroderma	Negative	Positive
Form	Peripheral neural involvement	Leprosy reaction	
I	Absent	Absent	
T	Localized, close to the skin lesion	Absent	
D	It can be intense, early, multiple	Reaction outbreak type 1 (all) or type 2 (positive sputum smear)	
V	Late, moderate, diffuse	Reactionary outbreak type 2	

Source: Lyon S & Grossi MAF. Leprosy. Rio de Janeiro: Medbook, 2013 (adapted). (24)

Table 2. Characteristics of the dimorphic--tuberculoid (DT) form according to the Ridley and Jopling Classification (1962)

Dimorphic--tuberculoid (DT)	
"Form"	Unstable; tends to the TT extreme.
Characterization of the lesions	Cutaneous similar to the TT form. They are usually satellites, smaller and more numerous around the main lesion.
Histopathological findings	Milder, extensive granulomas limited to the dermis, with

the formation of a narrow collagenous fibrous band just under the epidermis (Unna's band or Grenz's zone). Langhans-type multinucleated giant cells in varying numbers. Thickening of the nerves tends to be irregular, and usually the nerve filaments are more preserved.

Mitsuda's reaction	Positive
Bacilloscopy	Negative
IB	Can range from 0 to 2+
Operational Classification	Multibacillary
"Form"	Dimorphic--dimorphic (DD) Unstable; tends to one of the extremes, TT or VV.
Characterization of the lesions	Foveolar--eithymatopigmentary plaques, edematous; with a depressed nucleus, hypo-or normochromic or hypo-or anesthetic.
Histopathological findings	Traces of loose, diffusely distributed granulomas, with the presence of clear cytoplasmic epithelioid cells. Absence of multinucleated giant cells. Diffusely distributed mimicked lymphocytes in number. Neural fillets are mostly easy to identify and many show proliferation of Schwann cells. Excessive interstitial edema occurs in the dermis.
Mitsuda's reaction	Generally negative
Bacilloscopy	It can be nositiva
IB	Can range from 3+ to 4+
Operational Classification	Multibacillary
"Form"	Dimorphic--virchowian (DV) Unstable, tends to the extreme VV.
Characterization of the lesions	Cutaneous similar to the VV form, with nodules and infiltrations; more violaceous coloration, mainly on the face and in the ear pinnae. It may show as disseminated.
Histopathological findings	Moderate activation of macrophages. Presence of numerous lymphocytes compared to the VV form, forming poorly defined granulomas. Presence of plasma cells can occur. Easily identifiable neural filaments that show proliferation of Schwann cells or perineural fibroblasts, ("onion skin" appearance).
Mitsuda's reaction	Negative
Bacilloscopy	Positive
IB	Can range from 4+ to 5+
Operational Classification	Multibacillary

Source: Ridley DS, et al. (1966). (25) (Adapted);
Brazil, Ministerio da Saude (2019). (16)

Table 3. Treatment regimens for multibacillary (MB): 12 frames in up to 18 months

Rifampicin (RFM): monthly dose of 600 mg (2 capsules of 300 mg) with supervised administration.

Adult Dapsone (DDS): supervised monthly dose of 100 mg and a self-administered daily dose of 100 mg.
Clofazimine (CFZ): monthly dose of 300 mg (3 capsules of 100 mg) with supervised administration and a daily self-administered dose of 50 mg.

Rifampicin (RFM): monthly dose of 450 mg (1 capsule 150 mg and 1 capsule 300 mg) with supervised administration.

Child Dapsone (DDS): supervised monthly dose of 50 mg and a self-administered daily dose of 50 mg.
Clofazimine (CFZ): monthly dose of 150 mg (3 capsules of 50 mg) with supervised administration and a 50 mg dose self-administered every other day.

Source: Brazil, Ministry of Health (2019). (16)

Table 4. Treatment regimens for paucibacillary (PB): 6 tablets in up to 9 months

Rifampicin (RFM): monthly dose of 600 mg (2 capsules of 300 mg) with supervised administration.

Adult Dapsone (DDS): supervised monthly dose of 100 mg and self-administered daily dose of 100 mg.
Rifampicin (RFM): monthly dose of 450 mg (1 capsule 150 mg and 1 capsule 300 mg) with supervised administration.

Child Dapsone (DDS): supervised monthly dose of 50 mg and self-administered daily dose of 50 mg.

Source: Brazil, Ministry of Health (2019). (16)

Table 5. Doses for MDT adjustment according to the patient's body mass

Dapsone (DDS)	Rifampicin (RFM)	Clofazimine (CFZ)
1.5 mg/kg/day	10 mg/kg/day	1 mg/kg/day (daily dose) 5 mg/kg/day (monthly dose)

Source: Brazil, Ministry of Health (2019). (16)

Dapsone (DDS)	Rifampicin (RFM)	Clofazimine (CFZ)
1.5 mg/kg/day	10 mg/kg/day	1 mg/kg/day (daily dose) 5 mg/kg/day (monthly dose)

Source: Brazil, Ministry of Health (2019).¹⁶

Copyright: COPYRIGHT 2021 Universidade do Estado do Rio de Janeiro- Uerj
<https://www.e-publicacoes.uerj.br/>

Citação da fonte

Gomes, Andreia P., et al. "Leprosy: A clinical review." *Brazilian Journal of Health and Biomedical Sciences*, vol. 20, no. 2, July-Dec. 2021, pp. 151+. *Gale Academic OneFile*, link.gale.com/apps/doc/A705890418/AONE?u=capex&sid=bookmark-AONE&xid=c166f939. Accessed 1 Nov. 2022.